



SEPTEMBER 2023 EDITION

NEWSLETTER

RajaRajeswari Dental College & Hospital

DEPARTMENT OF PUBLIC HEALTH DENTISTRY

VOLUNTARY BLOOD DONATION CAMP ON 05/09/2023

A Voluntary Blood donation camp was organized and conducted on occasion of Teachers Day- September 2023 by the Department of Public Health Dentistry, RajaRajeswari Dental College and Hospital. The associating blood banks and organizations in the noble endeavour were:-

1. Blood bank- RajaRajeswari Medical College and Hospital.
2. Blood bank of Victoria hospital – Bangalore.
3. LION's Club- Bangalore South.

A total of **50 UNITS** of blood were donated collectively from the volunteer donors including Teaching, Non-Teaching Staff, Postgraduates, Interns and Undergraduates of RajaRajeswari Dental College and Hospital.



In addition all the Donors and Volunteers were tested for haemoglobin levels and blood grouping.

SWACHHTA HI SEWA CAMPAIGN ON 30/09/2023

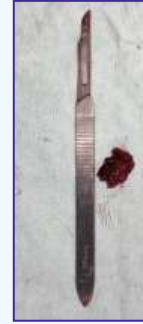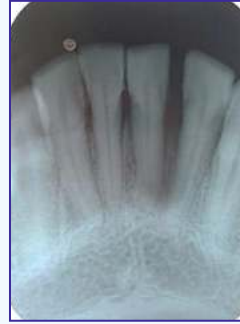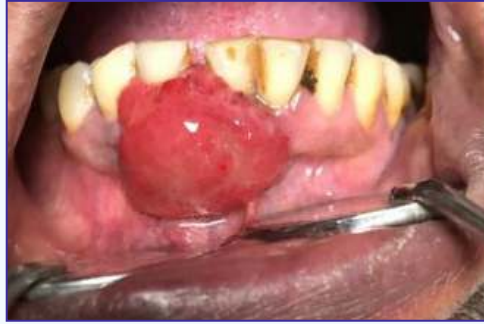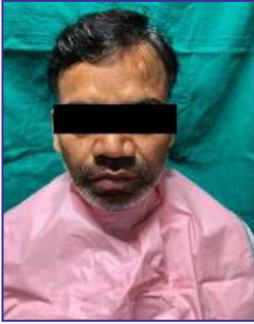The event was organised by NSS unit RajaRajeswari dental college and hospital. Theme of Swacchta Hi Sewa-2023 is 'Garbage Free India' with focus on visual cleanliness. Like earlier years the spirit of cleanliness activities is voluntarism/shramdaan. The focus of this year's Swachhta drive was the following list of activities

- Cleaning of the bus stand and around Doddaladamara premises: All the NSS volunteers and staff took part in 1 hour shramdaan activity of cleaning all bus stand and nearby shop premises. The footpaths on the sides of the big banyan tree was cleaned of plastics and other wastes and collected in garbage bags for safe disposal.
- Pledge taking drive: all the staff and students took pledge to create awareness of cleanliness, ensure proper segregation of waste and do shramdaan to create a clean country.



CASE OF THE MONTH

DEPARTMENT OF ORAL MEDICINE AND RADIOLOGY



A 35 years old male patient reported to the department with the complaint of growth in his lower front tooth region since 2 months. He first noticed the growth which was initially smaller in size and gradually increased to the present size in the duration of 2 months. On intra oral examination, A solitary pedunculated exophytic soft tissue growth covering the interdental region & approximately one third of clinical crown of 41 and 42 measuring about 2 x 2.25 cm extending from mesial aspect of 31 to distal aspect of 43 and SI from middle third of crown portion of 41, 31 till the labial vestibule, growth appears pink to deep red in colour and surface appears smooth and shiny. On palpation growth was soft in consistency; non-tender & bleeding was present on stimulus.

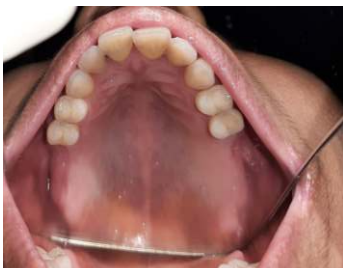On soft tissue examination, white plaque was present on the left buccal vestibule measuring about 2.5x2.5 cm extending superoinferiorly from 1cm below the level of occlusal plane till the buccal vestibule & mediolaterally from distal aspect of 33 till the distal aspect of 35 region and has cracked mud appearance. Lesion was non-scrapable and non-tender which is suggestive of Homogenous leukoplakia.

On hard tissue examination, dental caries i.r.t 47, attrition involving enamel and dentin i.r.t 26, 36, 46 with supragingival calculus and extrinsic stains were present.

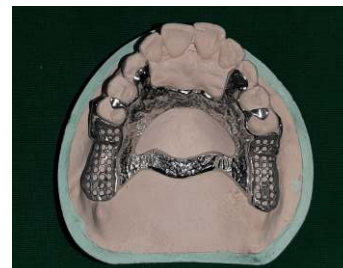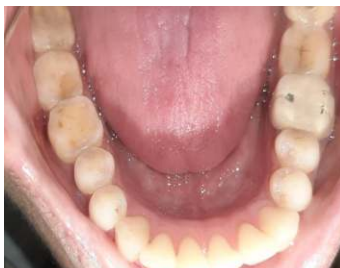Based on the clinical findings, a provisional diagnosis of pyogenic granuloma i.r.t 41, 42 was given. Peripheral ossifying fibroma and Peripheral giant cell granuloma were considered under differential diagnoses. Patient was subjected to radiographic examination, IOPAR i.r.t 41, 42 was done and it revealed horizontal bone loss in between 41 & 42 which is extending till the junction of cervical & middle third of root & also bone loss extending till cervical third of root i.r.t 31, 32 and mesial aspect of 41. The radiograph did not reveal calcifications/ossifications ruling out peripheral ossifying fibroma. Routine blood examination results were found to be within normal limits. Excisional biopsy was done and sent for histopathological examination and the microscopic features were suggestive of pyogenic granuloma in relation to 41 and 42.

DEPARTMENT OF PROSTHODONTICS CROWN AND BRIDGE

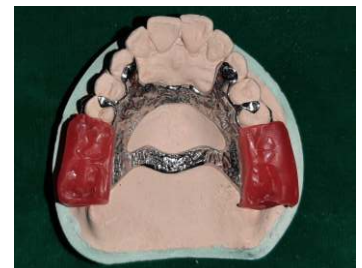PROSTHODONTIC REHABILITATION OF PARTIALLY EDENTULOUS MAXILLARY ARCH WITH CAST-PARTIAL DENTURE.



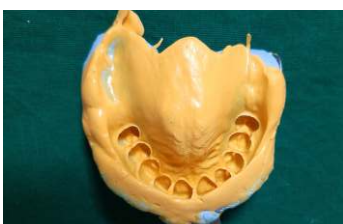Pre- operative intraoral photographs



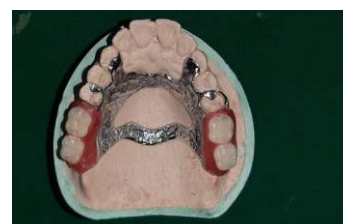CPD Framework fabrication



Jaw relation(Wax bite)made on framework

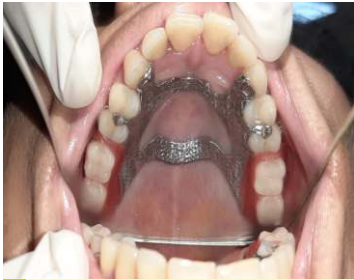

Final Impression made

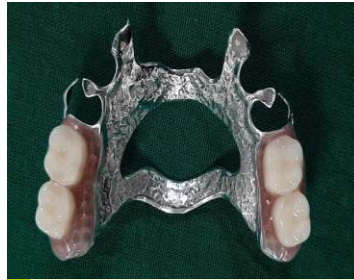

Teeth arrangement done

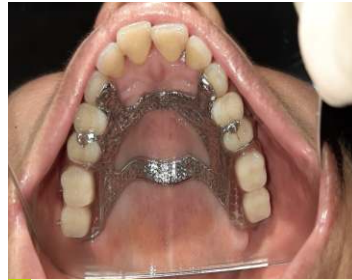PROSTHODONTIC REHABILITATION OF PARTIALLY EDENTULOUS MAXILLARY ARCH WITH CAST-PARTIAL DENTURE.



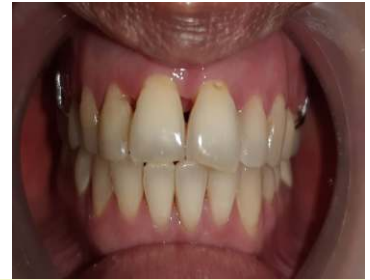Try-in of CPD



Final acrylized denture



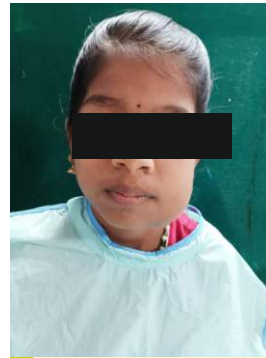Post-operative Photographs



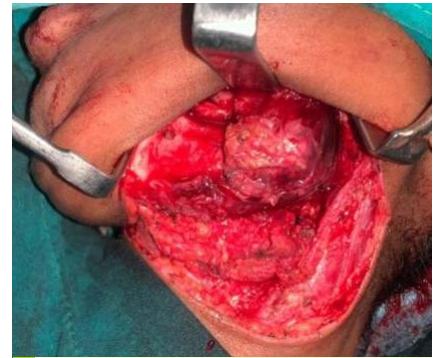
DEPARTMENT OF ORAL AND MAXILLOFACIAL SUREGURY

OSSIFYING FIBROMA OF RIGHT MANDIBLE

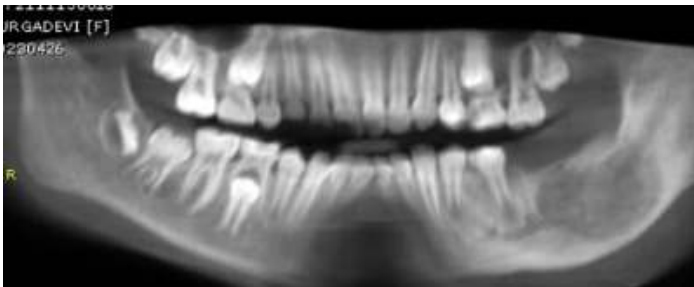
A 11-year-old female patient reported to RRDCH with asymptomatic mandibular swelling on the left side of face that radiographically illustrated a well-circumscribed expansile mass of the left mandibular body region with a sclerotic margin and ground-glass appearance. Incisional biopsy reported as benign fibro-osseous lesion, ossifying fibroma. The patient was treated by segmental mandibulectomy and reconstruction with iliac crest bone graft along with titanium reconstruction plate and screws. Post operative healing was uneventful.



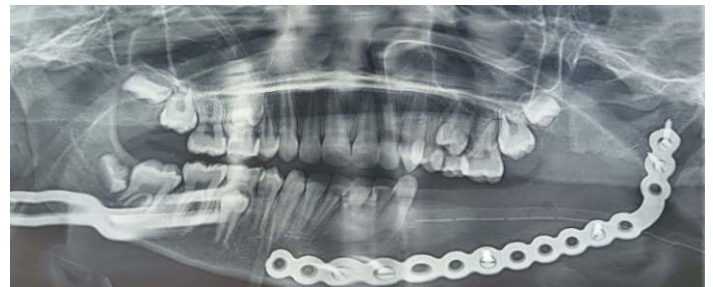Pre operative photo



Intra operative photo



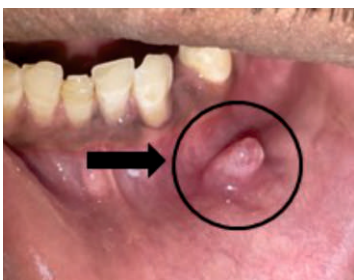Intra operative photo



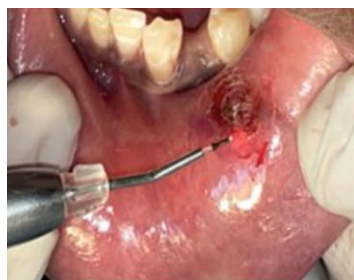Post Operative Radiograph

DEPARTMENT OF PERIODONTOLOGY

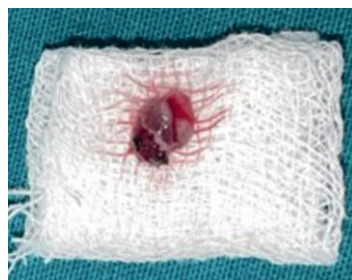MUCOCELE EXCISION WITH DIODE LASER



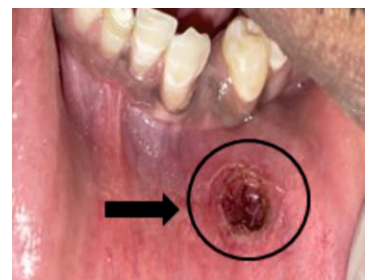Pre-operative view



Intra-operative view



Excised growth



Immediate post-operative view

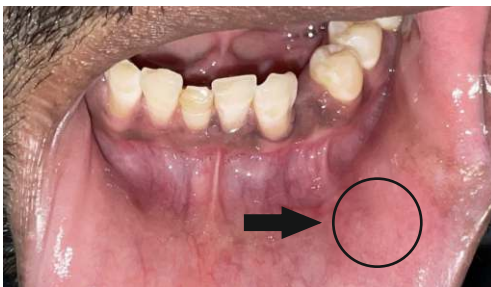Background: Mucocele is the most common lesion of the oral mucosa, which results from the accumulation of mucous secretion due to trauma and lip biting habits or alteration of minor salivary glands. They are mostly of two types based on histological features: extravasation and retention. Mucoceles can appear anywhere in the oral mucosa such as lip, cheeks and the floor of the mouth, but mainly appear in the lip. Diagnosis is mostly based on clinical findings. The most common location of the extravasation mucocele is the lower lip. Mucoceles are mostly seen in young patients but can affect all age groups.

MUCOCELE EXCISION WITH DIODE LASER

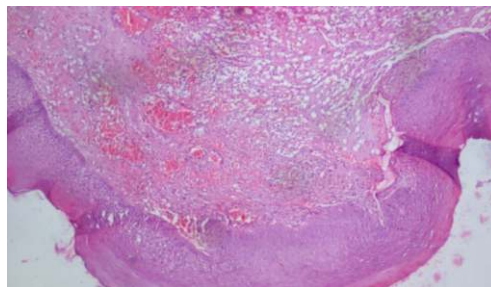
They are transparent cystic swellings ranging from the normal colour of oral mucosa to deep blue, soft in consistency and fluctuate on palpation. The treatment of choice is surgical excision.

Case Report: A 33-year old male patient reported to the Department of Periodontology with the complaint of swelling on the lower lip since 2 weeks. The patient first noticed the growth 2 weeks back, which was initially small and gradually increased to the present size. There were associated symptoms such as pus discharge, bleeding, pain or any kind of discomfort. Patient did not have any significant medical history. Clinical examination revealed a well-defined sessile growth measuring about 1.5×1.5 cm present on the lower lip. On palpation, the growth was soft to firm in consistency, immobile and non-tender. Based on clinical findings, a provisional diagnosis of traumatic fibroma involving the lower lip was made. The growth was excised with diode laser and the specimen sent for histopathological examination. The microscopic findings were suggestive of a mucocele. The operated area healed uneventfully with no adverse effects noted.

Conclusion: Diode laser can be used as an alternative to the scalpel for excision of growths in the oral cavity as they have the advantages of ensuring a clearer operating field owing to their better hemostatic control.



10 days post-operative view



Histopathologic picture showing stratified squamous epithelium, underlying fibrous stroma shows mucous like area depicting mixed salivary gland. Fibrous condensation evident around mucous pooling and mild inflammatory infiltrate noted.

DEPARTMENT OF PEDODONTICS AND PREVENTIVE DENTISTRY

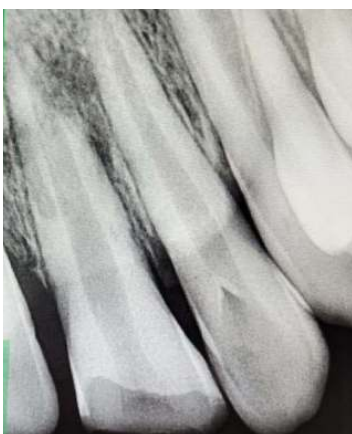ESTHETIC MANAGEMENT OF ELLIS CLASS IV FRACTURE IN PEDIATRIC PATIENT USING CAD-CAM TECHNOLOGY

A female patient aged 13 years reported to the Department of Pediatric and Preventive Dentistry, Rajarajeswari Dental College and Hospital with a chief complaint of pain and discoloration in the upper front tooth region and also complained of poor aesthetics causing difficulty to communicate with peers. Patient has given a history of trauma two years ago resulted in the fracture of the upper front tooth region. Intra oral examination revealed Ellis Class IV fracture in relation to 21 and Ellis Class I fracture in relation to 11. The necessary investigations were done.

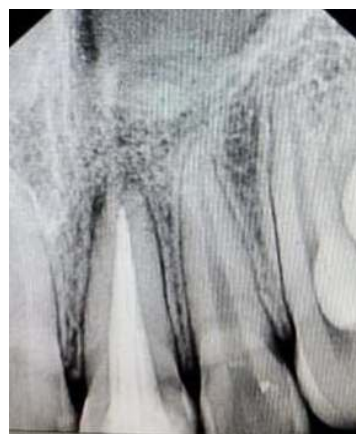Root canal therapy followed by permanent restoration was planned in relation to 21 and composite build up in relation to 11. A multi visit root canal therapy was carried out and considering her age and esthetic concerns, Zirconia crown using CAD-CAM technology was planned and performed. Crown preparation, fabrication and crown cementation using resin modified GIC was successfully completed.

ADVANTAGES OF CAD-CAM TECHNOLOGY

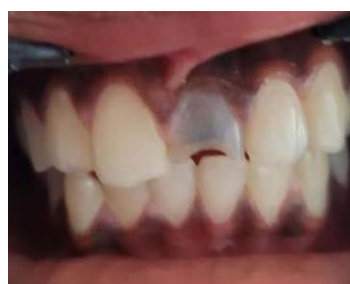The zirconia crowns fabricated Using CAD-CAM technology have shown high standards of precision, excellent aesthetics, and better mechanical properties such as increased hardness, improved marginal fit, bond strength, and biocompatibility along with decreased delivery time compared to other customized crowns such as PFM and All ceramic crowns.



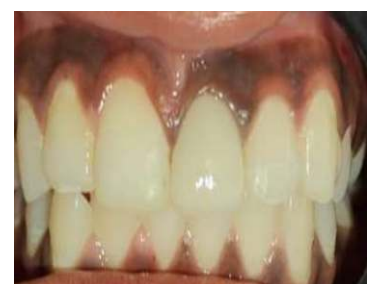Pre-op.



Post-op.



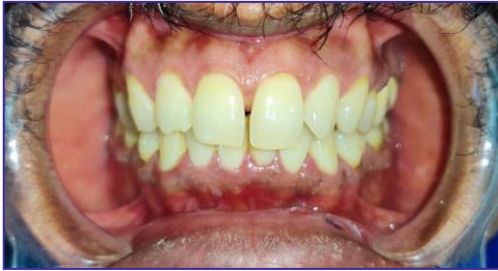Pre-op Photograph showing Ellis Class IV fracture



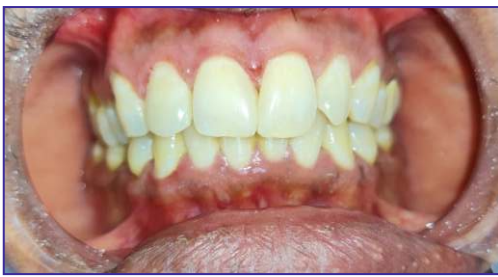Clinical photograph with Zirconia Crown

DEPARTMENT OF CONSERVATIVE DENTISTRY AND ENDODONTICS

MANAGEMENT OF MIDLINE DIASTEMA



PRE-OPERATIVE



POST-OPERATIVE

Background: Midline diastema is malocclusion having space in between maxillary or/and mandibular incisors. Maxillary incisors are more commonly affected than mandibular incisors. The growing demand for esthetics has made individuals more aware of the diastema which may be apparent during smiling. Composite restoration is one of the treatment modalities used to close the gap for esthetic concern.

Case Report: A 40 year old patient reported to the department seeking esthetic correction for his gap between the teeth. Medical and Dental histories were not significant. Clinical examination revealed 1mm of gap between maxillary central incisors. Hence, Composite restoration was done.

Conclusion: Composite restoration can be safely and reliably employed to treat Midline diastema.

DEPARTMENT OF ORTHODONTICS AND DENTOFACIAL ORTHOPEDICS

CASE REPORT

NAME: -----

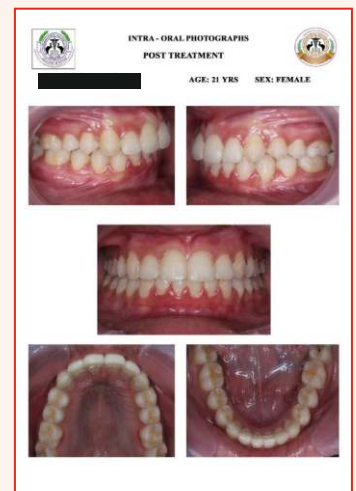
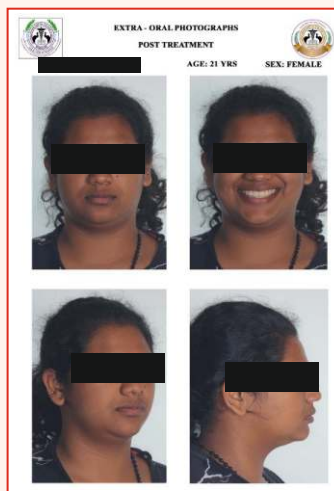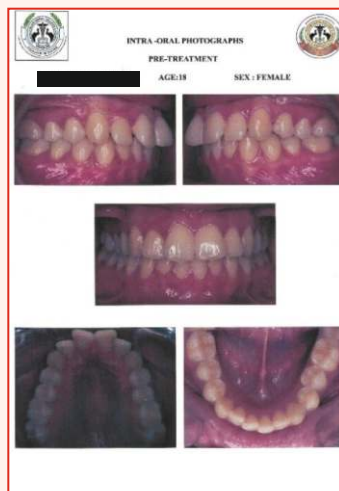
AGE/SEX: 21/F

OP.NO: -----

CHIEF COMPLAINT: Patient c/o irregularly placed upper and lower front teeth.

PROBLEM LIST: Angles Class I malocclusion with crowding in the upper and lower anterior teeth region.

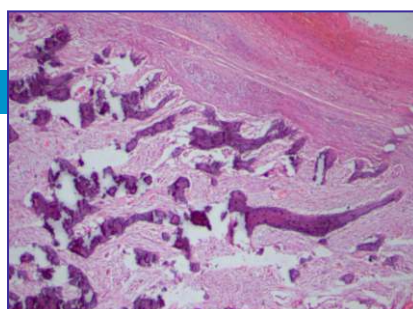
TREATMENT PLAN: Non-extraction line of treatment-MBT fixed appliance therapy



DEPARTMENT OF ORAL PATHOLOGY

AGGRESSIVE AMELOBLASTOMA

A 12 year old patient came with a chief complaint of swelling in the left cheek region since a year.




H&E stained section showing features Ossifying fibroma. (40x)

PUBLICATIONS

Sl. No.	TITLE	JOURNAL & ISSUE	AUTHORSHIP
DEPARTMENT OF ORAL MEDICINE AND RADIOLOGY			
1.	PREVALENCE OF NASAL SEPTAL DEVIATION AND ITS EFFECTS ON CONCHA BULLOSA, MAXILLARY SINUS MUCOSAL THICKNESS AND DEPTH OF PALATAL ARCH- AN OBSERVATIONAL CBCT STUDY	Journal of Indian Academy of Oral Medicine & Radiology September 2023; 33: 403-406	<ul style="list-style-type: none"> • Dr Syeda Muskan Jan • Dr Balaji P • Dr Poornima G
DEPARTMENT OF PERIODONTOLOGY			
1.	IS THERE ANY LINK BETWEEN CHRONIC PERIODONTITIS & MIGRAINE? A NARRATIVE REVIEW.	International Journal Of Scientific Research Issue -September 2023	<ul style="list-style-type: none"> • Dr. Alina Pauly • Dr. Sharika Gopinath
DEPARTMENT OF PEDODONTICS AND PREVENTIVE DENTISTRY			
1.	COMPARISON OF DISTRACTION TECHNIQUES USING SALIVARY BIOMARKERS DURING LOCAL ANESTHESIA ADMINISTRATION IN CHILDREN AGED 3-5YEARS: A CLINICAL STUDY	Indian Journal Of Dental Research Volume 34, Issue 2	<ul style="list-style-type: none"> • Dr Meghana S. B
DEPARTMENT OF ORTHODONTICS AND DENTOFACIAL ORTHOPEDICS			
1.	OBSTRUCTIVE SLEEP APNEA	Journal of Advanced Zoology September 2023 Vol 44, Issue S1	<ul style="list-style-type: none"> • Dr. Siddarth Arya • Dr. Shwetha G S • Dr. Shashikumar H C • Dr. Lokesh N K
2.	MANAGING CLASS II MALOCCLUSION USING TWIN BLOCK THERAPY IN A YOUNG ADOLESCENT PATIENT – A CASE REPORT	Journal Of Advanced Zoology September 2023 Vol 44, Issue S1	<ul style="list-style-type: none"> • Dr. Lokesh N K • Dr. Siddarth Arya • Dr. Vaishnavi S • Dr. Shashikumar H C
3.	CUSTOMISED FLASK FOR MAXILLOFACIAL PROSTHESIS – A NOVAL APPROACH	Journal Of Propulsion Technology September 2023 Vol 44, Issue 3	<ul style="list-style-type: none"> • Dr. Bharthi V S
DEPARTMENT OF PUBLIC HEALTH DENTISTRY			
1.	ORAL HEALTH STATUS TREATMENT NEEDS AMONG 12 YEARS OLD CHILDREN LIVING IN ORPHANAGES AND PARENTAL HOMES IN BANGALORE CITY: A CROSS SECTIONAL STUDY	International Journal of Community Medicine and Public Health, September 2023 Vol 10 Issue 9	<ul style="list-style-type: none"> • Dr.Padma K Bhat • Dr.Sushma S.G

BOOK PUBLICATIONS

Sl. No.	TITLE	PUBLISHER	ISSUE
DEPARTMENT OF PEDODONTICS AND PREVENTIVE DENTISTRY			
1.	Efficacy of various root canal irrigants in primary teeth- an overview	Current progress in medicine and medical research. Vol 8 ;chapter 7 (BP International)	<ul style="list-style-type: none"> • Dr. Jaya A.R



MEMORANDUM OF UNDERSTANDING

DEPARTMENT OF PERIODONTOLOGY

Student EXCHANGE PROGRAMME



WITH THE DEAN & THE PRINCIPAL, RRDCH, BANGALORE

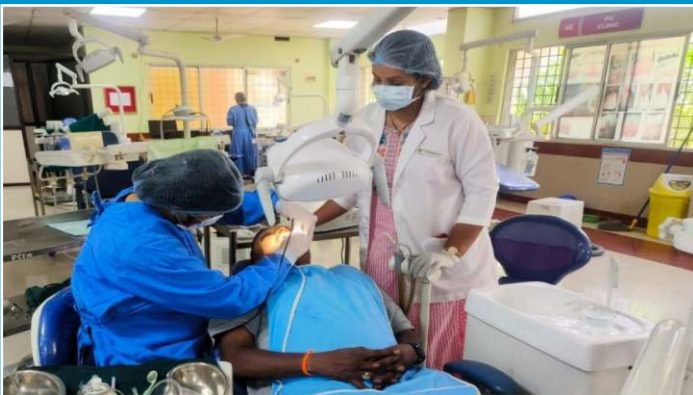As part of the MOU with Malabar Dental College & Research Centre, the Department of Periodontology at our institution hosted a post graduate student – Dr. Dhanasree K Balan as part of the student exchange programme on 31/08/2023 and 01/09/2023. The student participated in the academic as well as the clinical programme actively. She was posted in the CBCT section of the Department of Oral Medicine & Radiology and the Digital Dentistry Lab of the institution during her visit. In the Department of Periodontology, she assisted the post graduates in laser as well periodontal surgical procedures.



WITH THE DEPARTMENT OF PERIODONTOLOGY, RRDCH



AT THE DEPARTMENT OF ORAL MEDICINE & RADIOLOGY, RRDCH



WORKING IN THE DEPARTMENT OF PERIODONTOLOGY, RRDCH

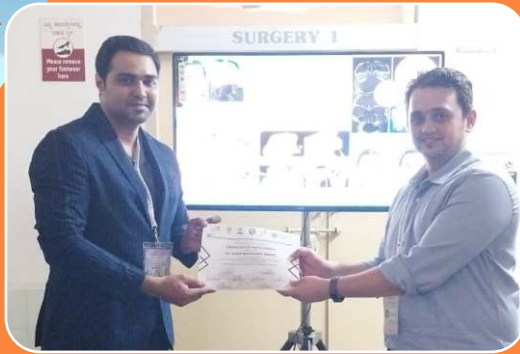

AT THE DIGITAL DENTISTRY LAB, RRDCH

Student Awards

DEPARTMENT OF PROSTHODONTICS CROWN AND BRIDGE

- Post graduate final exam result – 100%
- Under graduate final exam result – 100%



DEPARTMENT OF ORAL AND MAXILLOFACIAL SURGERY

Dr. Shaik Musaveer, I MDS won the best poster presentation award at Karnataka state chapter conference, AOMSI Dharwad

DEPARTMENT OF PROSTHODONTICS CROWN AND BRIDGE



Dr Shwetha Poovani & Dr Sindhu – Best poster awarded at IDA - Conference KLE Dental College, Bengaluru.

Faculty Awards

DEPARTMENT OF PEDODONTICS AND PREVENTIVE DENTISTRY



Certificate Course Awarded in Special Health Care Needs in Dentistry

INVITED LECTURES

DEPARTMENT OF PROSTHODONTICS CROWN AND BRIDGE

CONVENTION SCIENTIFIC PROGRAM - TOPIC: "T-Scan for digital analysis of Occlusion"

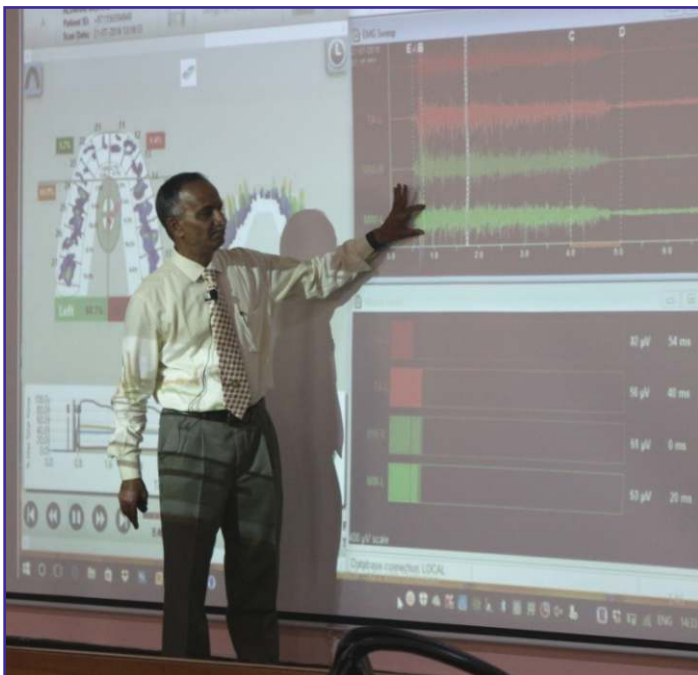
The Department of Prosthodontics in collaboration of IDA Bengaluru branch, has conducted convention scientific program - Preconvention course on the 22nd of September 2023.

Dr Prafulla Thumati Prof & Head of Oro-facial Pain Clinic at Rajarajeswari Dental College is a Prosthodontist and Implantologist who is specialized in full mouth rehabilitation and TMJ disorders .He is also an International Speaker for T-Scan Technology, Tekscan Inc. Boston since 2008 and Bio Research Inc. Milwaukee since 2012 conducting lectures and workshops on Occlusal Analysis and Biometrics in the Asia-Pacific region.



INVITED LECTURES - CONVENTION SCIENTIFIC PROGRAM - TOPIC: "T-Scan for digital analysis of Occlusion"

In Sep 2018; he got credentials for DTR (Disclusion Time Reduction) therapy: DTR Certified, Fellow, and Master; only fourth person in the world and the first person outside of America. Recently on May 22nd, 2021, he was awarded Fellow of the International College of Cranio-Mandibular Orthopedics. The program was graced by our Dean, Dr. Edwin Devadoss, Principal Dr. Girish H.C, Vice Principal Dr. Madhumathi Singh, Dr. Shwetha Poovani, HOD of Prosthodontics, Dr Rajeshwari C, Professor in Prosthodontics, IDA-EC Member , KLE Dental College, Dr Rohit S, Professor in Oral Surgery IDA-EC Member, RRDCH , all the Heads of other departments, Senior Professors, Faculty members, delegates from various Dental colleges, Private practitioners & PG students. A total of 16 participants benefited from this program.



Bengaluru, Karnataka, India
Rajajeswari College Of Engineering Digital Zone, Rajajeswari College Of Engineering, Bengaluru, Karnataka 560074, India
Lat 12.887431°

INVITED LECTURES - CONVENTION SCIENTIFIC PROGRAM - TOPIC: "T-Scan for digital analysis of Occlusion"



INVITED LECTURES

DEPARTMENT OF ORAL AND MAXILLOFACIAL SURGERY

Dr. Madhumati Singh and Dr. Mamatha N S at Karnataka state chapter conference, AOMSI Dharwad



Dr. Madhumati Singh

B.D.S. M.D.S. FIMSA, MFDS RCPS (GLASGOW)

PROFESSOR AND VICE PRINCIPAL
(Rajarajeswari Dental College and Hospital, Bangalore)

- B.D.S and M.D.S from GDCH, Nagpur University.
- Teaching Experience: 35 yrs

Membership:

- Association of Oral and Maxillofacial Surgeons of India
- Indian Dental Association
- The Royal College of Physicians and Surgeons of Glasgow
- Fellow of International Medical Sciences Academy
- ISOI (Indian society of Implantology)
- SOLA (Society of laser application) Karnataka Cancer Prevention Society
- International association for oral oncologist
- People for the Ethical Treatment of Animals (PETA)
- **Publications:** 65 (International 30 National -35)
- **Editor:** Journal of Oral health sciences and Research (RGUHS)
- International paper presentation- 4

INVITED LECTURES

AUTHOR OF BOOKS:

1.	Efficacy Of Lignocaine With Clonidine And Adrenaline In Minor Oral Surgical Procedure
2.	Tissue Engineering For Orofacial Region
3.	Intubation In Maxillofacial Surgery
4.	Mixed Radio-Lucent Radio-Opaque Lesions Of The Jaw
5.	Lateral Swellings Of The Neck
6.	Latest Concepts In Management Of Head Injury

MY JOURNEY OF BEING AN ORAL AND MAXILLOFACIAL SURGEON

I have the honor of becoming the first lady oral and maxillofacial surgeon, from Nagpur University. I have completed my BDS in year 1984 and MDS in year 1988 from government Dental College, Nagpur. In 1986 when I joined post graduation at GDCH, Nagpur no lady was allowed to take up PG seat in surgery. I took it as a challenge, believe me, I had a real tough time but I managed to pass in first attempt in 1988.

June 1988 first batch of BDS was appearing for final year with DCI inspection at KLES Belgaum. I along with my batch mates joined Belgaum and my career in academics started under Dr Khera. He gave me free hand to operate, next day of joining I operated a TMJ ankylosis case, on my own, which boosted my confidence.

In December 1990 I married a Bangalorean medical practitioner and shifted here, joined MRADC as UG teacher till 1995.

For 2 years I worked in Shymala Reddy dental college.

In 1997 I joined RRDC. I have started my department and established it with post graduate admission from 2007 with 2 admissions to 6 from 2012, I have PhD students under me.

Work life balance I have managed with very supportive spouse and two daughters, who are post graduate with engineering degree. It is a multitasking job for ladies, mother, daughter, wife, daughter in law, home maker and career oriented, but I managed it well, may be spiritual aspect of my personality, practice of yoga, meditation helped me to balance.

My advice to my students and junior colleagues, to be good human being first and treat your patient as your family members and do justice with them if you can. In Bhagvad Gita also shree Krishna says " if you do good karma, all good things will come back to you".

Dr. Madhumati Singh., B.D.S. M.D.S. FIMSA, MFDS RCPS, (GLASGOW)

PROFESSOR AND VICE PRINCIPAL., (Rajarajeswari Dental College and Hospital, Bangalore)

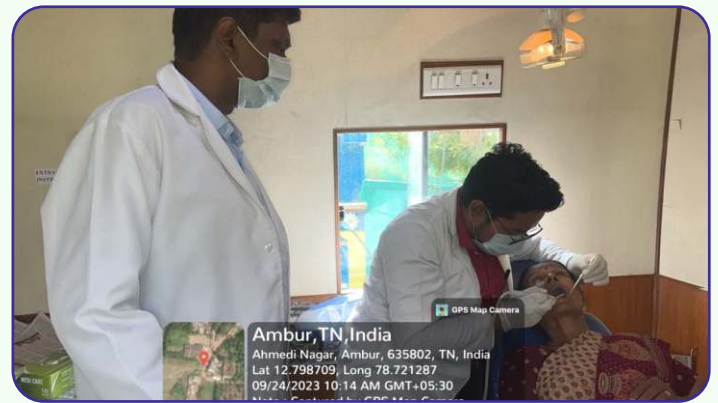• Excerpts from the annual Karnataka maxfax editorial by AOMSI

OUTREACH PROGRAM

DEPARTMENT OF ORAL MEDICINE AND RADIOLOGY



A free dental treatment camp was organised by Department of Public Health Dentistry, RRDCH, Bangalore in which Dr Atanu Das, an intern posted in our department took active participation in the camp held on 23rd September 2023 at Vaniyambadi and 24th September 2023 at Ambur, Tamilnadu.



DEPARTMENT OF PUBLIC HEALTH DENTISTRY

Sl. No.	Date	Place of Camp conducted
1.	01/09/2023	Rotary Bhavana, Magadi
2.	02/09/2023	GKBM- School, Magadi
3.	08/09/2023	Nirashritara Parihara Kendra
4.	21/09/2023	Ganigarapalya, Government School

OPD STATISTICS

DEPARTMENT OF ORAL MEDICINE AND RADIOLOGY

New cases	Old cases	Total cases	Patients per day
6359	5664	12023	572

OPD STATISTICS

SPECIAL CASE STATISTICS:

	Total number of cases
Pulpal And Periapical Diseases, Space Infections	790
Gingival and Periodontal Diseases	332
Mucosal Lesions, Oral Potentially Malignant Disorders, Malignancy	43
Trauma Cases	17
Bone Pathologies	04

	Total number of cases
Salivary Gland Diseases	01
Temporomandibular Diseases, Neuralgias and Muscle Diseases	08
Growths And Benign Conditions	02
Congenital Disorders	07
Radiation Induced Mucositis	01

DEPARTMENT SPECIFIC STATISTICS:

Space infection	14	Disc displacement with reduction	04	Avulsion	02	Glossitis	01	Anaemic stomatitis	01
Leukoplakia	07	Traumatic fibroma	02	Osteomyelitis	01	Chemical burn	01	Gingival cyst	01
Oral Lichen planus	02	Internal resorption	02	Myofascial pain dysfunction syndrome	01	Subluxation	03	Angular cheilitis	01
Frictional keratosis	02	Oral submucous fibrosis	05	Dental fluorosis	05	Dry socket	01	Soft tissue injury	05
Denture stomatitis	01	Smoker's melanosis	01	Gingival enlargement	02	Myofascial pain	02	Dentigerous cyst	01
Submucosal hemorrhage	01	Erythroplakia	01	Tobacco pouch keratosis	02	Condylar hyperplasia	01	Mucocele	01
Fracture cases	07	Candidal leukoplakia	01	Traumatic ulcer	04	Smoker's palate	07	Paresthesia of tongue	01
Radicular cyst	01	Geographic tongue	01	Radiation induced mucositis	01	Aphthous Ulcer	03	Mesiodens	01

DEPARTMENT OF PROSTHODONTICS CROWN AND BRIDGE

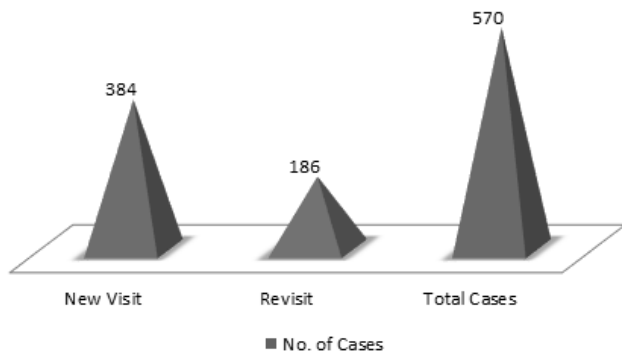
Total no of working days:	Total no of Cases treated:	New	Revisited
21	1331	390	941

DEPARTMENT OF ORAL AND MAXILLOFACIAL SURGERY

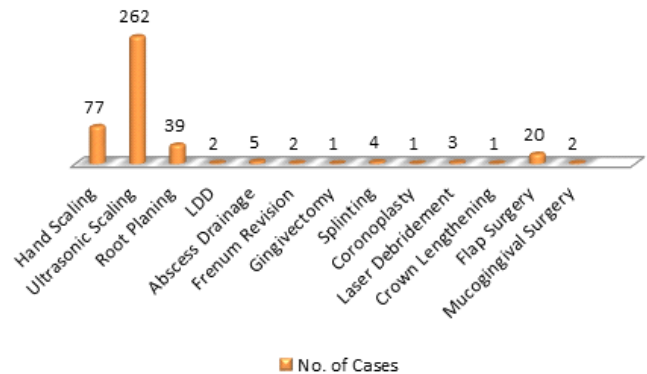
Total Cases	PG Cases	UG Cases	Major OT
1814	870	830	4

DEPARTMENT OF PERIODONTOLOGY

Case Break-up for Sept 2023



Treatment-wise cases done in Sept 2023



DEPARTMENT OF PEDODONTICS AND PREVENTIVE DENTISTRY

	SEP
Total	1410
Scaling	135
Topical fluoride	120
Pit and fissure sealants	125
G.I.C.	118
Amalgam	10
Composite	95
I.P.C	32
D.P.C	18
Pulp Therapy	90

RCT	68
Extraction	110
Space Maintainer	25
Minor orthodontics	08
Apexification	08
Stainless steel crown- Primary	68
Stainless steel crown- Permanent	26
Strip Crowns	12
Traumatic Injuries splinting	03
Minor surgical procedures	03

DEPARTMENT OF CONSERVATIVE DENTISTRY AND ENDODONTICS

STATISTICS FOR THE YEAR 2023

MONTH	No of working days	New visit	Re visit	Total	Average
SEPTEMBER	22	1049	929	1978	90

UG STATISTICS FOR THE YEAR 2023

MONTH	TOTAL NO OF CASES	AMALGAM	COMPOSITE	GIC	TF
SEPTEMBER	175	31	97	24	23

PG STATISTICS FOR THE YEAR 2023

MONTH	TOTAL NO OF CASES	AMALGAM	COMPOSITE	GIC	RCT	CROWN	P&C	INLAY	ONLAY	SURGERY
SEPTEMBER	558	00	76	69	231	14	10	00	00	00

OPD STATISTICS

DEPARTMENT OF ORTHODONTICS AND DENTOFACIAL ORTHOPEDICS

MONTH	OPD		TOTAL
	NEW	REVISIT	
SEPTEMBER 2023	774	1132	1906

DEPARTMENT OF PUBLIC HEALTH DENTISTRY

FROM OUTDOOR ACTIVITIES

MONTH	NO. OF DENTAL CAMPS	DENTAL CAMPS- NO OF CASES	PRIMARY HEALTH CENTER (URBAN) Chunchunkuppe	PRIMARY HEALTH CENTER (URBAN) Channasandra	TOTAL NO OF CASES IN CAMPS
SEPTEMBER	4	477	74	127	678

OPD SEPTEMBER MONTH STATISTICS

MONTH	TOTAL NO OF CASES
SEPTEMBER	220

TREATMENT WISE PATIENT STATISTICS FOR THE MONTH OF SEPTEMBER 2023

SL.NO	TREATMENT DONE	NUMBER OF PATIENTS
1.	Extraction	1
2.	Restoration	15
3.	Oral prophylaxis	59
4.	Pit and fissure sealant	03
5.	Fluoride	03
6.	Health Education	137
7.	Tobacco cessation counselling	20
	TOTAL	238

DEPARTMENT OF IMPLANTOLOGY

STATISTICS FOR THE MONTH OF SEPTEMBER 2023

MONTH	IMPLANT	OPD	PROSTHETIC	FAIL IMPLANT
SEPTEMBER	6	26	46	1

DEPARTMENT OF ORAL PATHOLOGY

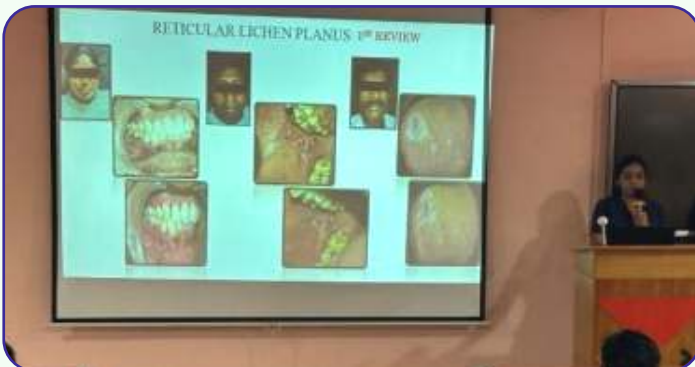OPD SEPTEMBER MONTH STATISTICS : 450

INTER DEPARTMENT MEET

DEPARTMENT OF ORAL MEDICINE AND RADIOLOGY



The monthly Interdepartmental Clinical Meet was conducted by the Department of Oral Medicine and Radiology on 21-09-2023 between 9.30 to 10.15 am. The event was conducted in the new smart class room. The topic of the clinical meet was **"Topical corticosteroids- Cognizance about forewarned is forearmed"**. The presenters for the day were second year postgraduate students, **Dr Samadrita Paul and Dr D Bhavishya**. The presenters talked about the role of topical corticosteroids in the management of oral mucosal lesions. They also highlighted the clinical applications and adverse effects associated with the drug. Following the presentation there was a **Q & A session** to address the queries of the audience. The event was attended by faculty, postgraduate students and interns. The event was successful in imparting knowledge on the above-mentioned topic.



Student Corner

DEPARTMENT OF ORAL MEDICINE AND RADIOLOGY

EXPERIENCE OF BECOMING AN INTERN BY Dr ABHA and Dr AFEEFA

As a student at RajaRajeswari Dental college, we learnt a lot and still in the process of learning during our internship postings. It's been a great opportunity to get hands-on-experience. Our experience of being a student was entirely different than being an intern. When we were students, it was just the theoretical knowledge whereas now being an intern we are applying theoretical knowledge practically. On one hand, we are getting to learn many new things and on other hand, being treated like a doctor is entirely a different feeling.


Listening to how our teachers interact with and create relationships with patients has helped us to know how to value our patients and treat them so that they feel comfortable. A huge part of dentistry is to build rapport with patients and creating space for them to share their questions and concerns without fear of judgement and here we get to see a perfect example how to do so.

PATIENT FEEDBACK

DEPARTMENT OF ORAL MEDICINE AND RADIOLOGY

29 patient's feedbacks were collected and all were positive regarding the services offered by the department and one had the issue with delay in x ray reporting which will be resolved.

DEPARTMENT OF PERIODONTOLOGY

 DEPARTMENT OF PERIODONTOLOGY
PATIENT FEEDBACK

To provide patient friendly facilities in the hospital, we need your valuable feedback & suggestions.

Name of Patient : Kalavathi
Age/Gender : F
Address : Ramnagar
Phone No : 880968043
OP No : 2309010308
Email ID :

How do you rate the information given at the Reception Counter?
☒ Excellent ☐ Good ☐ Average ☐ Poor

How do you rate your reception by oral health care providers during your first visit as a patient?
☒ Excellent ☐ Good ☐ Average ☐ Poor

How do you rate the overall cleanliness of the department and the facilities provided?
☒ Excellent ☐ Good ☐ Average ☐ Poor

How do you rate your experience during a subsequent visit to the department?
☒ Excellent ☐ Good ☐ Average ☐ Poor


How do you rate the treatment services provided at the department?
☒ Excellent ☐ Good ☐ Average ☐ Poor


How do you rate the emergency treatment services at the hospital?
☒ Excellent ☐ Good ☐ Average ☐ Poor ☐ Not availed

How do you rate the treatment charges at this hospital?
☒ Excellent ☐ Good ☐ Average ☐ Poor

What is your overall opinion about the hospital?
☒ Excellent ☐ Good ☐ Average ☐ Poor

Suggestions (if any)

Signature of Patient  Date: 14/9/23

 DEPARTMENT OF PERIODONTOLOGY
PATIENT FEEDBACK

To provide patient friendly facilities in the hospital, we need your valuable feedback & suggestions.

Name of Patient : Anala
Age/Gender : F
Address : Ramnagar
Phone No : 9400929106
OP No : 2303060004
Email ID :

How do you rate the information given at the Reception Counter?
☒ Excellent ☐ Good ☐ Average ☐ Poor

How do you rate your reception by oral health care providers during your first visit as a patient?
☒ Excellent ☐ Good ☐ Average ☐ Poor

How do you rate the overall cleanliness of the department and the facilities provided?
☒ Excellent ☐ Good ☐ Average ☐ Poor

How do you rate your experience during a subsequent visit to the department?
☒ Excellent ☐ Good ☐ Average ☐ Poor


How do you rate the treatment services provided at the department?
☒ Excellent ☐ Good ☐ Average ☐ Poor


How do you rate the emergency treatment services at the hospital?
☒ Excellent ☐ Good ☐ Average ☐ Poor ☐ Not availed

How do you rate the treatment charges at this hospital?
☒ Excellent ☐ Good ☐ Average ☐ Poor

What is your overall opinion about the hospital?
☒ Excellent ☐ Good ☐ Average ☐ Poor

Suggestions (if any)

Signature of Patient  Date: 12/9/23

 DEPARTMENT OF PERIODONTOLOGY
PATIENT FEEDBACK

To provide patient friendly facilities in the hospital, we need your valuable feedback & suggestions.

Name of Patient : Nidhi
Age/Gender : 27/F
Address : Bangalore
Phone No : 861838455
OP No : 230109027
Email ID :

How do you rate the information given at the Reception Counter?
☒ Excellent ☐ Good ☐ Average ☐ Poor

How do you rate your reception by oral health care providers during your first visit as a patient?
☒ Excellent ☐ Good ☐ Average ☐ Poor

How do you rate the overall cleanliness of the department and the facilities provided?
☒ Excellent ☐ Good ☐ Average ☐ Poor

How do you rate your experience during a subsequent visit to the department?
☒ Excellent ☐ Good ☐ Average ☐ Poor


How do you rate the treatment services provided at the department?
☒ Excellent ☐ Good ☐ Average ☐ Poor


How do you rate the emergency treatment services at the hospital?
☒ Excellent ☐ Good ☐ Average ☐ Poor ☐ Not availed

How do you rate the treatment charges at this hospital?
☒ Excellent ☐ Good ☐ Average ☐ Poor

What is your overall opinion about the hospital?
☒ Excellent ☐ Good ☐ Average ☐ Poor

Suggestions (if any)

Signature of Patient  Date: 8/9/23

 DEPARTMENT OF PERIODONTOLOGY
PATIENT FEEDBACK

To provide patient friendly facilities in the hospital, we need your valuable feedback & suggestions.

Name of Patient : Shashikala
Age/Gender : F/45
Address : Pattanagar
Phone No : 9400929106
OP No : 2309108101
Email ID :

How do you rate the information given at the Reception Counter?
☒ Excellent ☐ Good ☐ Average ☐ Poor

How do you rate your reception by oral health care providers during your first visit as a patient?
☒ Excellent ☐ Good ☐ Average ☐ Poor

How do you rate the overall cleanliness of the department and the facilities provided?
☒ Excellent ☐ Good ☐ Average ☐ Poor

How do you rate your experience during a subsequent visit to the department?
☒ Excellent ☐ Good ☐ Average ☐ Poor


How do you rate the treatment services provided at the department?
☒ Excellent ☐ Good ☐ Average ☐ Poor

How do you rate the emergency treatment services at the hospital?
☒ Excellent ☐ Good ☐ Average ☐ Poor ☐ Not availed

How do you rate the treatment charges at this hospital?
☒ Excellent ☐ Good ☐ Average ☐ Poor

What is your overall opinion about the hospital?
☒ Excellent ☐ Good ☐ Average ☐ Poor

Suggestions (if any)

Signature of Patient  Date: 22/9/23

DEPARTMENT OF PEDODONTICS AND PREVENTIVE DENTISTRY

DEPARTMENT OF PEDIATRIC AND PREVENTIVE DENTISTRY
OUT PATIENT FEEDBACK FROM

NAME: Muskan DATE: 28/07/23
AGE/SEX: 5/F OP REGISTRATION NO: 87140
CONTACT NO: 9900463056

RATE YOUR EXPERIENCE WITH THE FOLLOWING ASPECTS OF YOUR VISIT

TITLE	VERY GOOD	GOOD	FAIR	POOR
RECEPTIONIST DESK				
EASE OF APPOINTMENT				
TREATMENT DONE				
TREATING DOCTOR				

OVER ALL SATISFACTION: Very Satisfactory
VERY SATISFACTORY / SATISFIED / UN SATISFIED

SIGNATURE OF PATIENT: Muskan

DEPARTMENT OF PEDIATRIC AND PREVENTIVE DENTISTRY
OUT PATIENT FEEDBACK FROM

NAME: Pranjal DATE: 28/07/23
AGE/SEX: 12 OP REGISTRATION NO: 2307190322
CONTACT NO: 9900463056

RATE YOUR EXPERIENCE WITH THE FOLLOWING ASPECTS OF YOUR VISIT

TITLE	VERY GOOD	GOOD	FAIR	POOR
RECEPTIONIST DESK				
EASE OF APPOINTMENT				
TREATMENT DONE				
TREATING DOCTOR				

OVER ALL SATISFACTION: Very Satisfactory
VERY SATISFACTORY / SATISFIED / UN SATISFIED

SIGNATURE OF PATIENT: Pranjal

DEPARTMENT OF PEDIATRIC AND PREVENTIVE DENTISTRY
OUT PATIENT FEEDBACK FROM

NAME: Arushi B DATE: 11/07/23
AGE/SEX: 10/F OP REGISTRATION NO: 2307190322
CONTACT NO: 9900463056

RATE YOUR EXPERIENCE WITH THE FOLLOWING ASPECTS OF YOUR VISIT

TITLE	VERY GOOD	GOOD	FAIR	POOR
RECEPTIONIST DESK				
EASE OF APPOINTMENT				
TREATMENT DONE				
TREATING DOCTOR				

OVER ALL SATISFACTION: Very Satisfactory
VERY SATISFACTORY / SATISFIED / UN SATISFIED

SIGNATURE OF PATIENT: Arushi

DEPARTMENT OF PEDIATRIC AND PREVENTIVE DENTISTRY
OUT PATIENT FEEDBACK FROM

NAME: Riya DATE: 14/7/23
AGE/SEX: 11/F OP REGISTRATION NO: 2307190322
CONTACT NO: 9900463056

RATE YOUR EXPERIENCE WITH THE FOLLOWING ASPECTS OF YOUR VISIT

TITLE	VERY GOOD	GOOD	FAIR	POOR
RECEPTIONIST DESK				
EASE OF APPOINTMENT				
TREATMENT DONE				
TREATING DOCTOR				

OVER ALL SATISFACTION: Very Satisfactory
VERY SATISFACTORY / SATISFIED / UN SATISFIED

SIGNATURE OF PATIENT: Riya

DEPARTMENT OF PROSTHODONTICS CROWN AND BRIDGE

RAJA RAJESWARI DENTAL COLLEGE AND HOSPITAL, BANGALORE.

AAC/ ANNEXURE / PATIENT SERVICE FEEDBACK

NAME: Gayathri Bani AGE: 52
ADDRESS: 243, 11th Cross, 1st Stage, 11th Block, H.B.R. Layout, Bangalore TELEPHONE NO.: 9900463056
SERVICES TAKEN FROM RRDCH: Crown DATE: 22/8/2023
HOSPITAL REGISTRATION NO: 28395

SL. NO	QUESTION	YES	NO
1	Are you aware of the availability of the extent of services at RRDCH?	<u>yes</u>	
2	Did you notice the display boards of these services at RRDCH?	<u>yes</u>	
3	Was the information easy to get from these display boards?	<u>yes</u>	
4	Did you get a copy of Patient information booklet/pamphlet, at RRDCH, having the study material on the availability of the whole range of services at RRDCH?		
5	Were the display boards adequate in number and optimally located?	<u>yes</u>	
6	Was the information clear and adequate?	<u>yes</u>	
7	Was the services promptly provided to you on the first visit?	<u>yes</u>	
8	Please specify the time it took to get your first assessment after you registered with RDCH services.	<u>yes</u>	
9	Were you given patient hearing in respect to your problem at the time of assessment?	<u>yes</u>	
10	Was he/she able to you all the information clearly and adequately?	<u>yes</u>	
11	Were you reassessed on your subsequent visits and advised treatment / guidance?	<u>yes</u>	
12	Are you satisfied with the process of your assessment at RRDCH?	<u>yes</u>	

PLEASE GIVE YOUR SUGGESTIONS Good Service provided by the Hospital Overall 9 am Satisfaction with The Facilities, Services & The Treatment, Gayathri S. Sankar

DEPARTMENT OF IMPLANTOLOGY

PATIENT COMPLAINTS /FEEDBACK FORM

NAME: Megha Date: 14/09/2023
AGE/SEX: 28/F
OP REGISTRATION NUMBER:
CONTACT NUMBER: 8050551009, 9743141003
NATURE OF COMPLAINT:

NATURE OF FEEDBACK:

All the staff and seniors are very kind and supportive. Service is very good. The doctor who take care my case is very kind and nice human being. Thank you for your valuable service & treatment.

SIGNATURE OF PATIENT: Megha

PATIENT COMPLAINTS /FEEDBACK FORM

NAME: Kavitha Jagannath Date: 14/9/23
AGE/SEX: 49
OP REGISTRATION NUMBER:
CONTACT NUMBER: 9739003660
NATURE OF COMPLAINT:

NATURE OF FEEDBACK:

The treatment and the followup done by Dr. Mallesh was extremely commendable. Very happy with the overall experience of tooth implant. Dr. Mallesh was very patient and explained in detail the procedure before every sitting.

SIGNATURE OF PATIENT: Kavitha

DEPARTMENT OF CONSERVATIVE DENTISTRY AND ENDODONTICS



DEPARTMENT OF CONSERVATIVE DENTISTRY AND ENDODONTICS

PATIENT FEEDBACK

To provide patient friendly facilities in the hospital, we need your valuable feedback & suggestions.

Name of Patient : Shiva Shankar
Age/Gender : 41/M
Address : Rajmangal, Nagar
Phone No : 9916790025
OP No : 2102080006
Email ID : -

How do you rate the information given at the Reception Counter?
☐ Excellent ☒ Good ☐ Average ☐ Poor

How do you rate your reception by oral health care providers during your first visit as a patient?
☐ Excellent ☒ Good ☐ Average ☐ Poor

How do you rate the overall cleanliness of the department and the facilities provided?
☐ Excellent ☒ Good ☐ Average ☐ Poor

How do you rate your experience during a subsequent visit to the department?
☐ Excellent ☒ Good ☐ Average ☐ Poor

How do you rate the treatment services provided at the department?
☐ Excellent ☒ Good ☐ Average ☐ Poor

How do you rate the emergency treatment services at the hospital?
☐ Excellent ☒ Good ☐ Average ☐ Poor ☐ Not availed

How do you rate the treatment charges at this hospital?
☐ Excellent ☐ Good ☐ Average ☐ Poor

What is your overall opinion about the hospital?
☐ Excellent ☒ Good ☐ Average ☐ Poor

Suggestions (if any)

Signature of Patient

Date: 06/09/23



DEPARTMENT OF CONSERVATIVE DENTISTRY AND ENDODONTICS

PATIENT FEEDBACK

To provide patient friendly facilities in the hospital, we need your valuable feedback & suggestions.

Name of Patient : Chinnelal
Age/Gender : 57/M
Address : Mudalpalaya, Bangalore
Phone No : 9844135825
OP No : 2203030053
Email ID : -

How do you rate the information given at the Reception Counter?
☐ Excellent ☒ Good ☐ Average ☐ Poor

How do you rate your reception by oral health care providers during your first visit as a patient?
☐ Excellent ☒ Good ☐ Average ☐ Poor

How do you rate the overall cleanliness of the department and the facilities provided?
☐ Excellent ☐ Good ☒ Average ☐ Poor

How do you rate your experience during a subsequent visit to the department?
☐ Excellent ☒ Good ☐ Average ☐ Poor

How do you rate the treatment services provided at the department?
☒ Excellent ☐ Good ☐ Average ☐ Poor

How do you rate the emergency treatment services at the hospital?
☐ Excellent ☒ Good ☐ Average ☐ Poor ☐ Not availed

How do you rate the treatment charges at this hospital?
☐ Excellent ☐ Good ☒ Average ☐ Poor

What is your overall opinion about the hospital?
☐ Excellent ☒ Good ☐ Average ☐ Poor

Suggestions (if any)

Signature of Patient

Date: 21/09/23



DEPARTMENT OF CONSERVATIVE DENTISTRY AND ENDODONTICS

PATIENT FEEDBACK

To provide patient friendly facilities in the hospital, we need your valuable feedback & suggestions.

Name of Patient : Shilpa
Age/Gender : 20/F
Address : Ramanagar
Phone No : 8660860291
OP No : 2012050017
Email ID : -

How do you rate the information given at the Reception Counter?
☒ Excellent ☐ Good ☐ Average ☐ Poor

How do you rate your reception by oral health care providers during your first visit as a patient?
☐ Excellent ☒ Good ☐ Average ☐ Poor

How do you rate the overall cleanliness of the department and the facilities provided?
☒ Excellent ☐ Good ☐ Average ☐ Poor

How do you rate your experience during a subsequent visit to the department?
☐ Excellent ☒ Good ☐ Average ☐ Poor

How do you rate the treatment services provided at the department?
☒ Excellent ☐ Good ☐ Average ☐ Poor

How do you rate the emergency treatment services at the hospital?
☒ Excellent ☐ Good ☐ Average ☐ Poor ☐ Not availed

How do you rate the treatment charges at this hospital?
☒ Excellent ☐ Good ☐ Average ☐ Poor

What is your overall opinion about the hospital?
☐ Excellent ☒ Good ☐ Average ☐ Poor

Suggestions (if any)

Signature of Patient

Date: 9/09/23



DEPARTMENT OF CONSERVATIVE DENTISTRY AND ENDODONTICS

PATIENT FEEDBACK

To provide patient friendly facilities in the hospital, we need your valuable feedback & suggestions.

Name of Patient : Uma Maheshwar
Age/Gender : 40/M
Address : Banashankar
Phone No : 9900192313
OP No : 2306240191
Email ID : -

How do you rate the information given at the Reception Counter?
☐ Excellent ☒ Good ☐ Average ☐ Poor

How do you rate your reception by oral health care providers during your first visit as a patient?
☐ Excellent ☒ Good ☐ Average ☐ Poor

How do you rate the overall cleanliness of the department and the facilities provided?
☐ Excellent ☒ Good ☐ Average ☐ Poor

How do you rate your experience during a subsequent visit to the department?
☒ Excellent ☐ Good ☐ Average ☐ Poor

How do you rate the treatment services provided at the department?
☐ Excellent ☒ Good ☐ Average ☐ Poor

How do you rate the emergency treatment services at the hospital?
☐ Excellent ☐ Good ☐ Average ☐ Poor ☐ Not availed

How do you rate the treatment charges at this hospital?
☐ Excellent ☐ Good ☒ Average ☐ Poor

What is your overall opinion about the hospital?
☒ Excellent ☐ Good ☐ Average ☐ Poor

Suggestions (if any)

Signature of Patient

Date: 18/09/23

DEPARTMENT OF ORTHODONTICS AND DENTOFACIAL ORTHOPEDICS

RRDCH/NABH/ORTHO/07

Patient Complaints/ Feedback Form

Date 30/09/23

Name: Ranjith
Age/sex: 18/Male
Op Registration number: 2307010158
Contact number: 7259338637
Nature of complain:

Nature of feedback:

- Organized Dept and convenient to approach.
- Hygienic environment with sterilized equipments. and frequent sanitization
- Comfortable treatment procedures

Signature of patient
Ranjith

RRDCH/NABH/ORTHO/07

Patient Complaints/ Feedback Form

Date 30/9/23

Name: Surabhi
Age/sex: 19/F
Op Registration number: 64727
Contact number: 9164530560
Nature of complain:

Nature of feedback:

The department is well organized and functions systematically. The Doctors addressed my concerns. Sterilization is Good. The Doctors are attending to us on time.

Surabhi K.M
Signature of patient



RajaRajeswari Dental College and Hospital, Bengaluru

14, Ramohalli Cross, Mysore Road, Bengaluru-560074. KARNATAKA. Phone: 080 28437150, Fax: 080 28437468.

E-mail: principalrrdch@gmail.com www.rrdch.org www.rrdch.edu.in