



OCTOBER 2023 EDITION

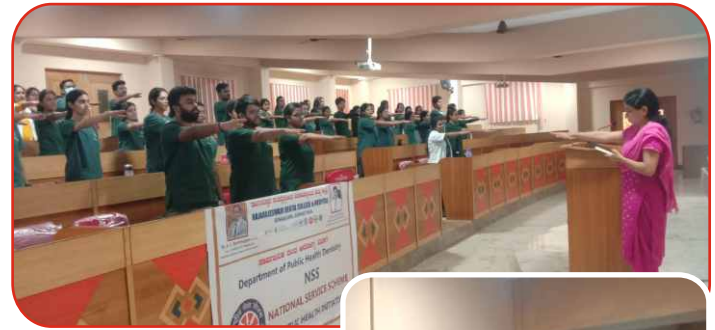RajaRajeswari Dental College & Hospital

NEWSLETTER



DEPARTMENT OF PUBLIC HEALTH DENTISTRY

RASHTRIYA EKATA DIVAS (NATIONAL UNITY DAY) - Date: 31st October 2023



Events organised: Unity awareness lecture & Unity pledge

Objective of the event: The NSS unit RajaRajeswari Dental College and Hospital organised national unity day on 31st October 2023 to commemorate the 148th birth anniversary of the IRON MAN OF INDIA - SARDAR VALLABHBHAI PATEL and create a sense of inherent strength and resilience of our people to with stand threats to security, unity and integrity of the country.

Number of beneficiaries: 85 students and staff

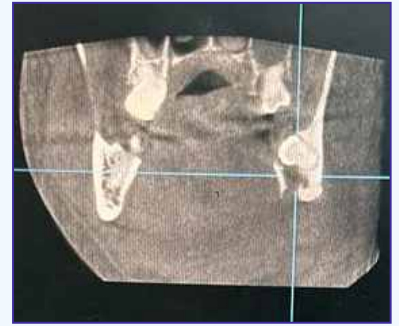
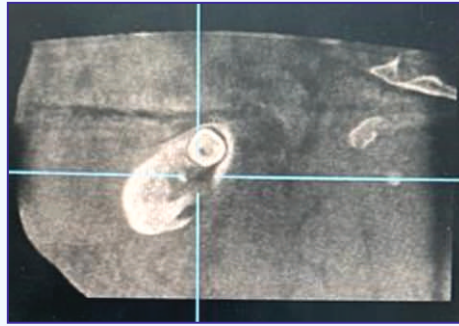
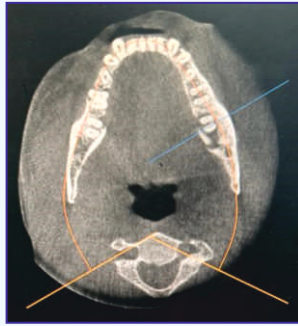
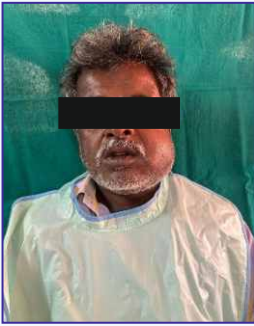Brief outline of the event:

- A lecture was rendered by Dr.Aruna.C.N. (Prof and HOD, Department of Public Health Dentistry) who emphasised the paramount importance of unity and highlighted how Sardar Patel's efforts led to the integration of princely states into a united India. She encouraged all present to uphold the core values of unity and diversity.
- The programme was culminated by pledge or oath taking ceremony which embarked the spirit that everyone should follow the path shown by Sardar Patel, keeping the nation as their first priority and working for unity and integrity



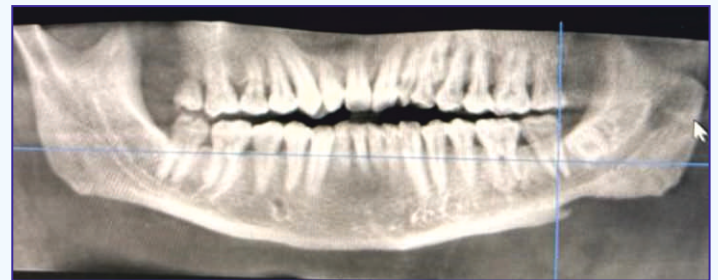
CASE OF THE MONTH

DEPARTMENT OF ORAL MEDICINE AND RADIOLOGY



OSTEOMYELITIS INVOLVING LEFT LOWER BORDER OF MANDIBLE

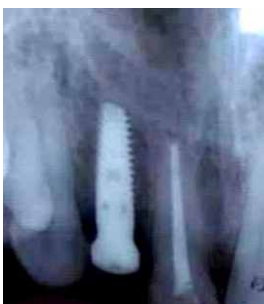A 45 years old male patient reported to the department with the complaint of swelling in his left side of face since 3 days with difficulty in opening mouth. He also gives history of occasional pain in his left lower back tooth since 10 months which used to subside after taking medications. He visited a private dental hospital for the same and various investigations were carried out including radiographs and FNAC. He also gives history of pus discharge from the left lower border of mandible after FNAC. On extra oral examination, a diffuse swelling was present on left middle third of face measuring about 7x7cm, swelling was firm in consistency and tender on palpation. Restricted mouth opening of about 15mm was present. Healing scar was present on the left lower border of mandible.



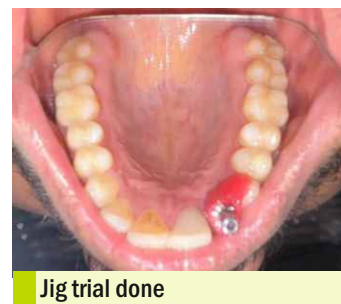Intraorally, buccal vestibular tenderness was present in relation to 37, 38. Provisional diagnosis of cellulitis secondary to chronic non-suppurative osteomyelitis was given. CBCT reveals erosion of inferior border of mandible with formation of Codman's triangle in the lingual cortical plate in relation to 37, 38 region and radiographic diagnosis of chronic osteomyelitis was given.

DEPARTMENT OF PROSTHODONTICS CROWN AND BRIDGE

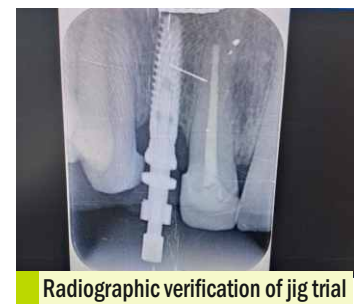PROSTHODONTIC REHABILITATION OF IMPLANT PLACED IN AESTHETIC ZONE



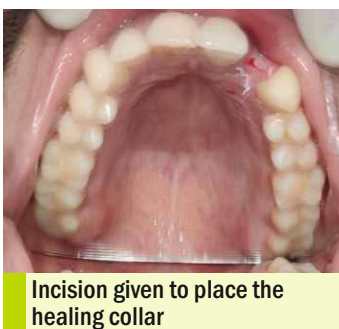
Pre -operative radiograph showing satisfactory osseointegration



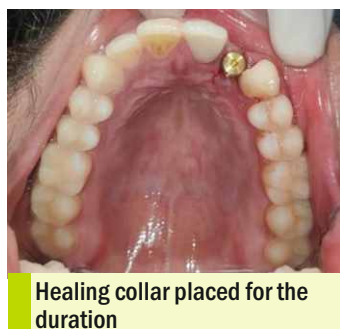Jig trial done



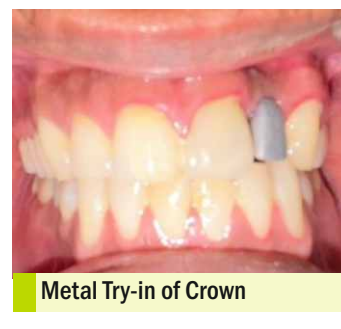Radiographic verification of jig trial



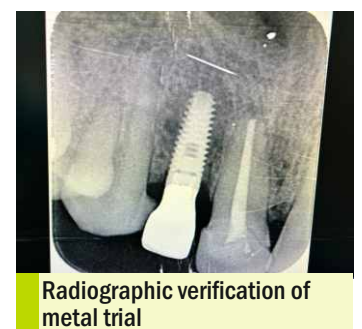Incision given to place the healing collar



Healing collar placed for the duration

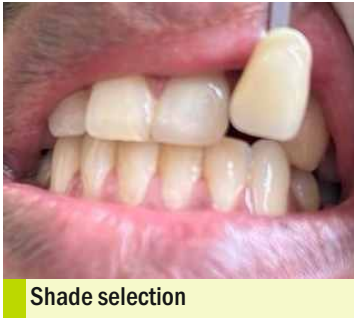

Metal Try-in of Crown

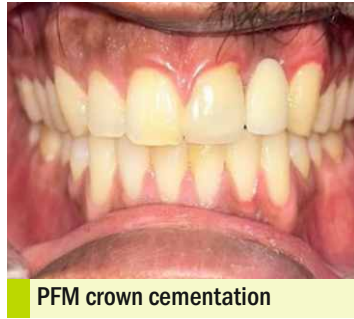

Radiographic verification of metal trial

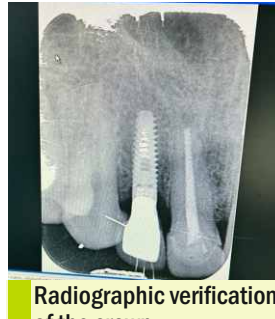PROSTHODONTIC REHABILITATION OF IMPLANT PLACED IN AESTHETIC ZONE



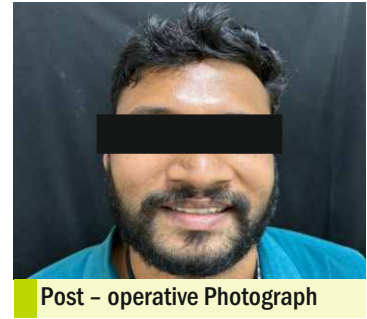Shade selection



PFM crown cementation



Radiographic verification of the crown

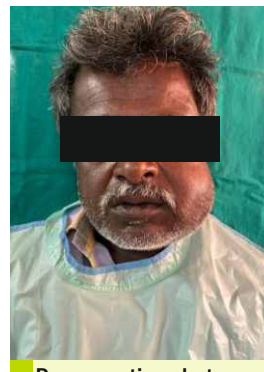

Post – operative Photograph

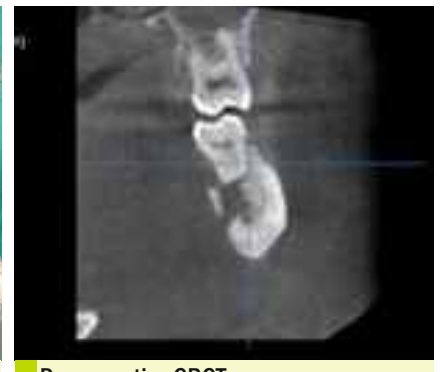DEPARTMENT OF ORAL AND MAXILLOFACIAL SUREGERY

OSTEOMYELITIS OF THE MANDIBLE

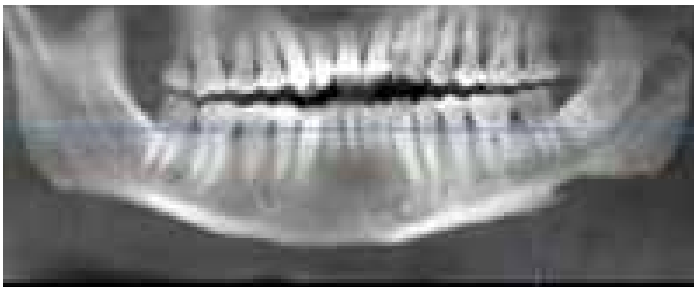
A 48-year-old man reported to the department with the complaint of swelling on the left side of the face with an extraorally draining sinus in the left antero-inferior border of the mandible. The patient gave history of pain in the lower left back of the mandible since 2 months. Patient was evaluated and advised radiographic investigations. Radiographic findings revealed sequestra in 37 region and the patient was diagnosed as osteomyelitis of mandible. Patient was treated with incision and drainage followed by extraction of 37 and lingual cortex removal (sequestrectomy) under IV antibiotic support. Postoperative healing was uneventful.



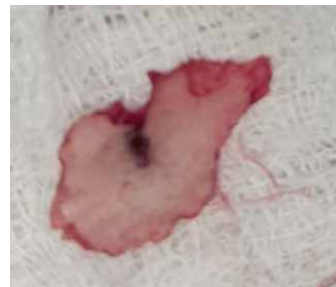Pre operative photo



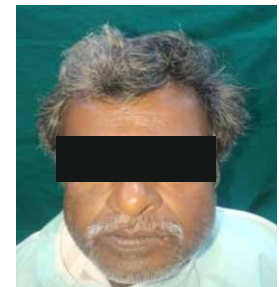Pre operative CBCT



Pre operative radiograph



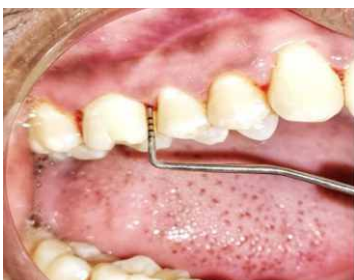Sequestra



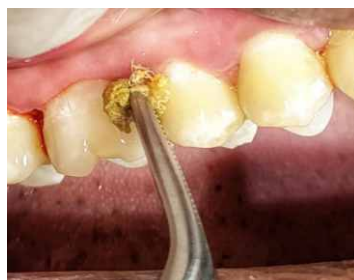Post Operative photo

DEPARTMENT OF PERIODONTOLOGY

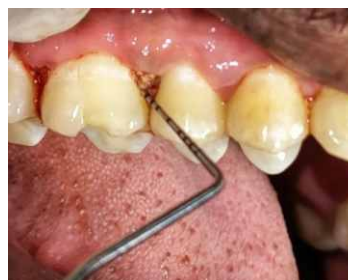LOCAL DRUG DELIVERY USING TETRACYCLINE FIBRES



Pre-operative



Intra-operative

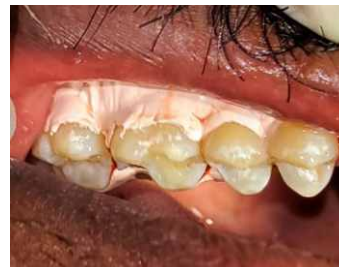

Tetracycline fibres

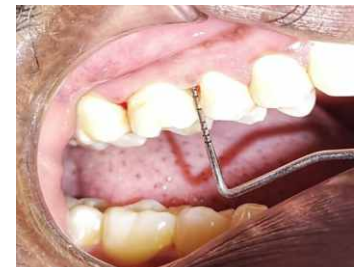Periodontitis is a polymicrobial disease which is initiated by dental plaque. Scaling and root planing remains the cornerstone of periodontal therapy. However, microorganisms can invade host tissues and may not be eliminated completely by mechanical therapy. Hence, LDD into the periodontal pockets has been advocated to deliver the drug directly to the site of infection. A 31-year old male patient reported with the complaint of food lodgement in the right upper back tooth region since 2 months.

LOCAL DRUG DELIVERY USING TETRACYCLINE FIBRES

On clinical examination, calculus was observed with probing pocket depth of 4-6mm. Complete ultrasonic scaling was done with root planing followed by placement of tetracycline fibres (Periodontal Plus AB) with respect to 15,16,17. Pocket depth was recorded at baseline and 2 months with reduction in pocket depth noted. Thus, tetracycline fibres can be used adjunctive to scaling and root planing for pocket reduction.



Periodontal dressing placed



Post operative (2 months)

DEPARTMENT OF PEDODONTICS AND PREVENTIVE DENTISTRY

NON-SURGICAL MANAGEMENT OF PRIMARY MOLAR WITH AN ACUTE ALVEOLAR ABSCESS IN A PEDIATRIC PATIENT

A male patient aged 8 years reported to the Department of Pediatric and Preventive Dentistry, Rajarajeswari Dental College and Hospital with a chief complaint of pain and swelling in the lower left back tooth region since 5 days causing difficulty in mastication, disturbance in sleep and unesthetic appearance.

Extraoral examination revealed a diffuse solitary swelling which was measuring 3 x 2 cm on left lower third of face extending anteroposteriorly from chin to the angle of mandible and superoinferiorly extending from corner of mouth to the body of the mandible, which was firm in consistency. Skin over the swelling appears stretched with local rise in temperature (Fig 1) and submandibular lymph nodes soft, tender and palpable.

Intraoral examination revealed mixed dentition with the fair OHI-S Index and deep dentinal caries in relation to 74 with vestibular obliteration and tenderness (Fig 2). The IOPAR shows radiolucency involving pulp in relation to 74 (Fig 3).

Considering the root length and age of the patient pulp therapy followed by stainless steel crown was planned in relation to 74. A multi visit pulp therapy was carried out under systemic antibiotics and once the tooth was asymptomatic obturation was done and stainless steel crown cementation using luting GIC was successfully completed (Fig 4). On follow up postoperative healing was satisfactory.



Figure 1

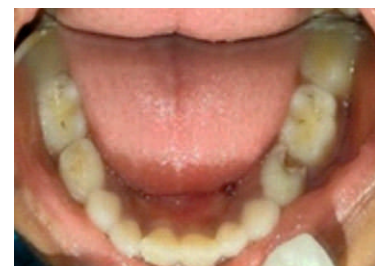

Figure 2

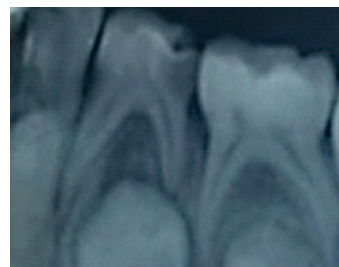
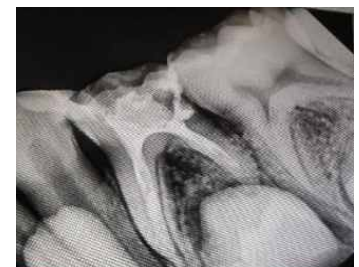

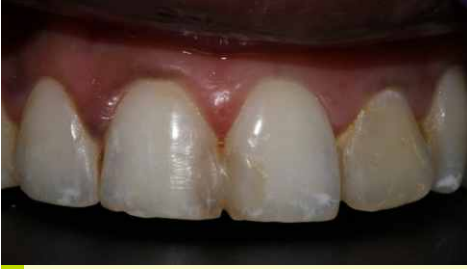Figure 3



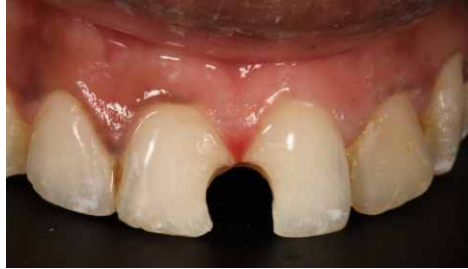DEPARTMENT OF CONSERVATIVE DENTISTRY AND ENDODONTICS

MANAGEMENT OF DISCOLOURED ANTERIOR RESTORATION

Background: Discoloration of restorative materials is an unwanted effect on esthetic dental resin composites, even though it is inevitable in the oral environment. Discoloration can be caused by intrinsic and (or) extrinsic factors. Incomplete polymerization of the resin composites leaves unreacted monomers, which can cause discoloration by aging and subsequent reactions with other substances. Discoloration can also occur through water sorption and food intake. Since the foods consumed contain a variety of coloring agents, they can alter the colour of the resin composites through absorption and/or adsorption of colorants during the long period of exposure. The growing demand for esthetics has made individuals more aware of the discoloured restorations which may be apparent during smiling. Composite re-restoration is one of the treatment modalities for esthetic concern.



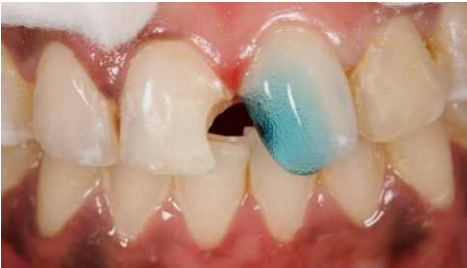PRE - OPERATIVE



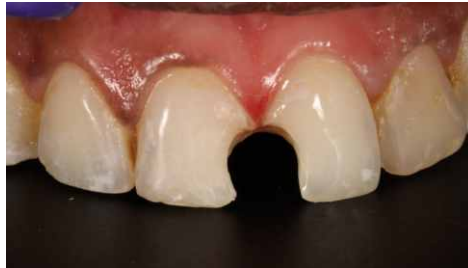REMOVAL OF OLD
RESTORATION AND
TOOTH PREPARATION

Case Report: A 28 year old patient reported to the department seeking esthetic correction for his discoloured anterior restoration. Medical and Dental histories were not significant. Clinical examination revealed discoloured composite restoration between maxillary central incisors. Hence, Composite re-restoration was done.

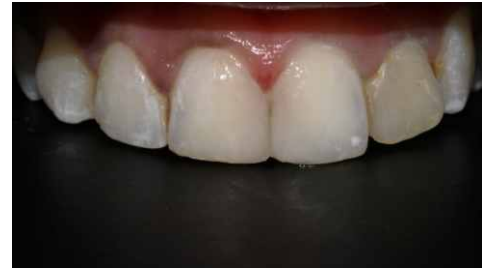Conclusion: Composite re-restoration can be safely and reliably employed to treat discoloured restorations.



ETCHING THE TOOTH SURFACE



APPLICATION OF BONDING AGENT



POST-OPERATIVE

DEPARTMENT OF ORTHODONTICS AND DENTOFACIAL ORTHOPEDICS

CASE REPORT

NAME:

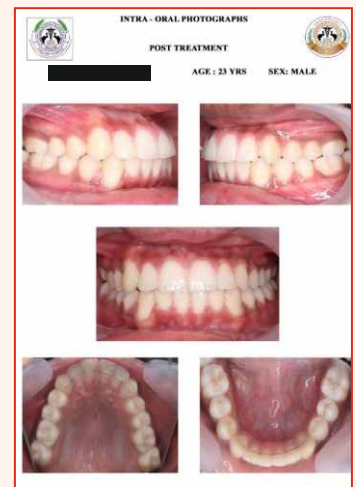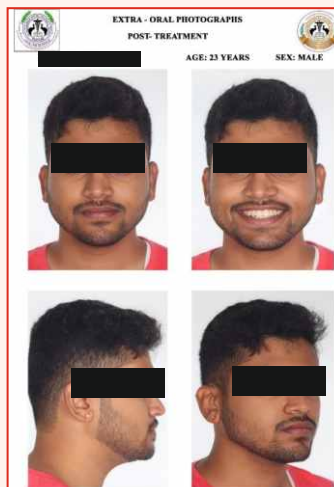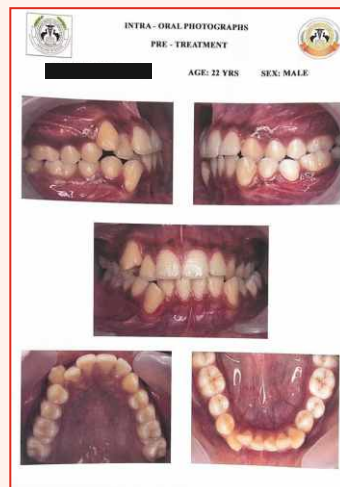
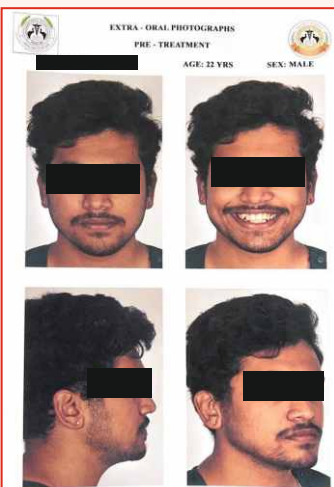AGE/SEX: 23/M

OP.NO:

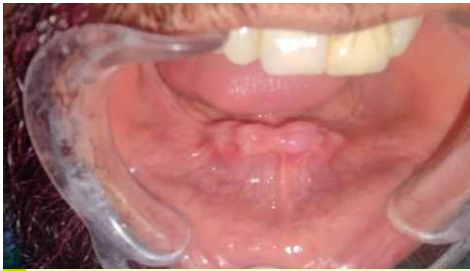CHIEF COMPLAINT: Patient c/o irregularly placed upper and lower front teeth.

PROBLEM LIST: Angles Class I malocclusion with crowding in the upper and lower anterior teeth region.

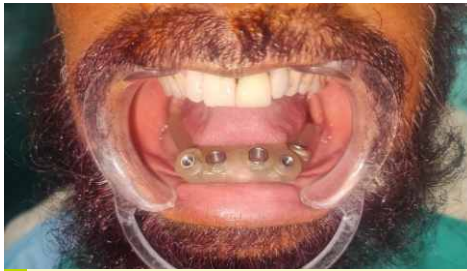TREATMENT PLAN: Non-extraction line of treatment-MBT fixed appliance therapy



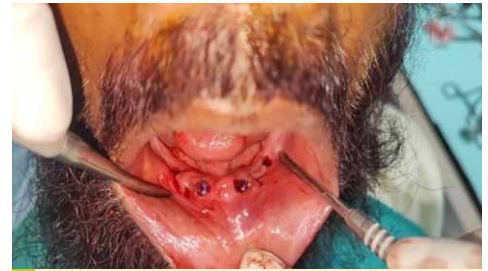DEPARTMENT OF ORAL IMPLANTOLOGY



PRE OP IMAGE



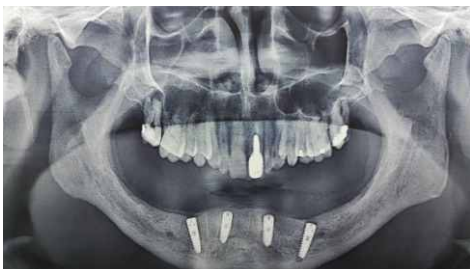SURGICAL GUIDE



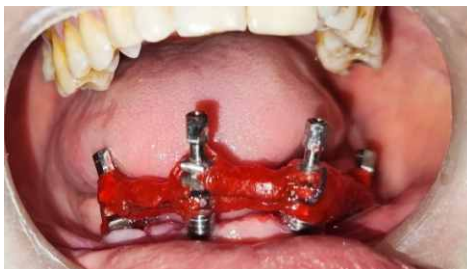IMPLANT PLACEMENT

A 56 y/o male patient reported to our department with completely edentulous lower arch and wanted implant supported fixed prosthesis for the same.

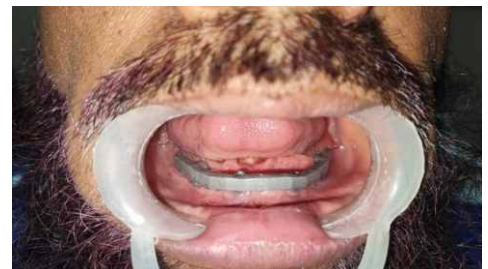After CBCT evaluation, all on 4 implants were placed using surgical guide (flapless procedure) and implant supported hybrid prosthesis was delivered after 3 months.



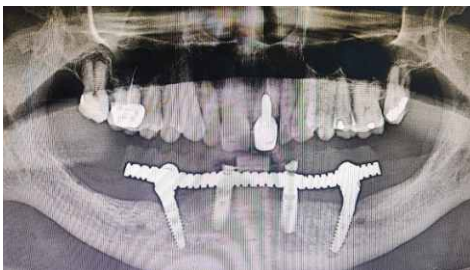PROSTHETIC PHASE



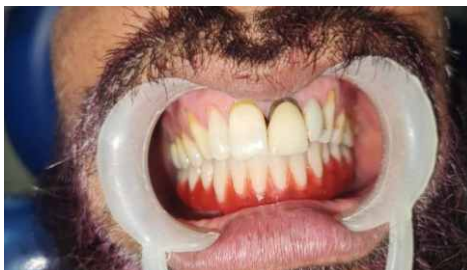PROSTHETIC PHASE



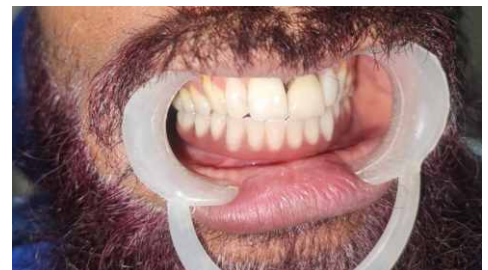PROSTHETIC PHASE



PROSTHETIC PHASE



PROSTHETIC PHASE



FINAL PROSTHESIS

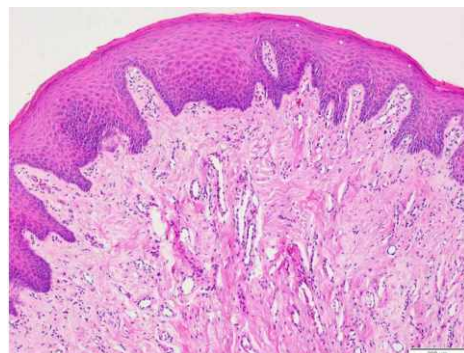
DEPARTMENT OF ORAL PATHOLOGY

FIBRO-EPITHELIAL HYPERPLASIA

A 75 year old female patient came with a chief complaint of swelling on the left gingival region since 2 months.

Intra oral examination revealed pedunculated, irregular surfaced soft tissue growth in 24, 25 alveolar ridge region, measuring about 3cms x 2cms. Growth was non tender and firm on palpation. Based on clinical features provisional diagnosis of irritational fibroma was given. The lesion was surgically excised under local anaesthesia based on provisional diagnosis. The tissue specimen was sent for histopathological examination. H& E stained section revealed hyper keratinised stratified squamous epithelium with underlying fibrous connective tissue. Connective tissue showed bundles of collagen fibers, coursing in an irregular pattern. Mild acute inflammatory infiltrate comprising polymorphonuclear leucocytes were noted.

The histopathological features were suggestive of fibro-epithelial hyperplasia. The patient was advised to maintain a scrupulous oral hygiene and was advised to come for regular checkup. The patient was reviewed after one month. Wound healing was satisfactory.



H&E stained section showing features of Fibro-epithelial hyperplasia. (20x)

PUBLICATIONS

Sl. No.	TITLE	JOURNAL & ISSUE	AUTHORSHIP
DEPARTMENT OF ORAL MEDICINE AND RADIOLOGY			
1.	Artificial Intelligence in Maxillofacial Radiology by Leaps and Bounds	Journal of Advanced Zoology 2023; 44 (s-3); 549-558.	<ul style="list-style-type: none"> • Dr D Bhavishya • Dr Mahesh Kumar T.S • Dr Poornima C
DEPARTMENT OF PERIODONTOLOGY			
1.	Efficacy of Locally Delivered 2% Grape seed Extract on Porphyromonas Gingivalis and Fusobacterium Nucleatum	Journal- Innovations Issue -September 2023	<ul style="list-style-type: none"> • Dr. Savitha .S
2.	Clinical Comparison Of Photodynamic Therapy With Methylene Blue And Malachite Green Adjunctive To SRP In Chronic Periodontitis	Journal of Advanced Zoology 2023; 44 (s-3); 600-605.	<ul style="list-style-type: none"> • Dr. Alina Pauly • Dr. Vinay kumar Ramachandra
3.	Effect of Laser as An Adjunct to Nonsurgical Periodontal Treatment on serum inflammatory markers in Patients with Chronic Periodontitis: A Clinico microbiological study	Journal of Advanced Zoology 2023; 44 (s-3); 627-632.	<ul style="list-style-type: none"> • Dr. Rithesh .K • Dr. M.S Nalini • Dr. R.S. Senthil Rajan
DEPARTMENT OF ORTHODONTICS AND DENTOFACIAL ORTHOPEDICS			
1.	Computational Fluid Dynamics And Its Solicitation In Dentistry- An Update And Review Of Literature	Journal of Advanced Zoology, October 2023 Vol 44 Issue S-3	<ul style="list-style-type: none"> • Dr. Mayank Trivedi • Dr. Rajkumar S Alle
DEPARTMENT OF PUBLIC HEALTH DENTISTRY			
1.	Patient Record Maintenance Among Private Dental Practitioners In Bangalore City	Journal of Advanced Zoology, October 2023 Vol 44 Issue S-3	<ul style="list-style-type: none"> • Dr. Prasanna Kumar Y S • Dr. Shweta Somasundara Y • Dr. Aruna C N

DEPARTMENT OF ORAL MEDICINE AND RADIOLOGY



Dr. Poornima G., Professor was awarded with “BEST TEACHER” for the academic year 2022-2023 on 27th Graduation Day held on 9th October 2023.

Faculty Awards

DEPARTMENT OF PROSTHODONTICS CROWN AND BRIDGE



Dr. Shwetha Poovani was felicitated to acknowledge her constant support provided to IPS Bengaluru branch in conducting and executing numerous programs at the national and state level.

DEPARTMENT OF PEDODONTICS AND PREVENTIVE DENTISTRY



Faculty Awards



A certificate was awarded to Dr Nagarathna C for her understanding on the prognostic factors of tooth avulsion and replantation at 44th ISPPD National Conference -Ahmedabad, October 2023.

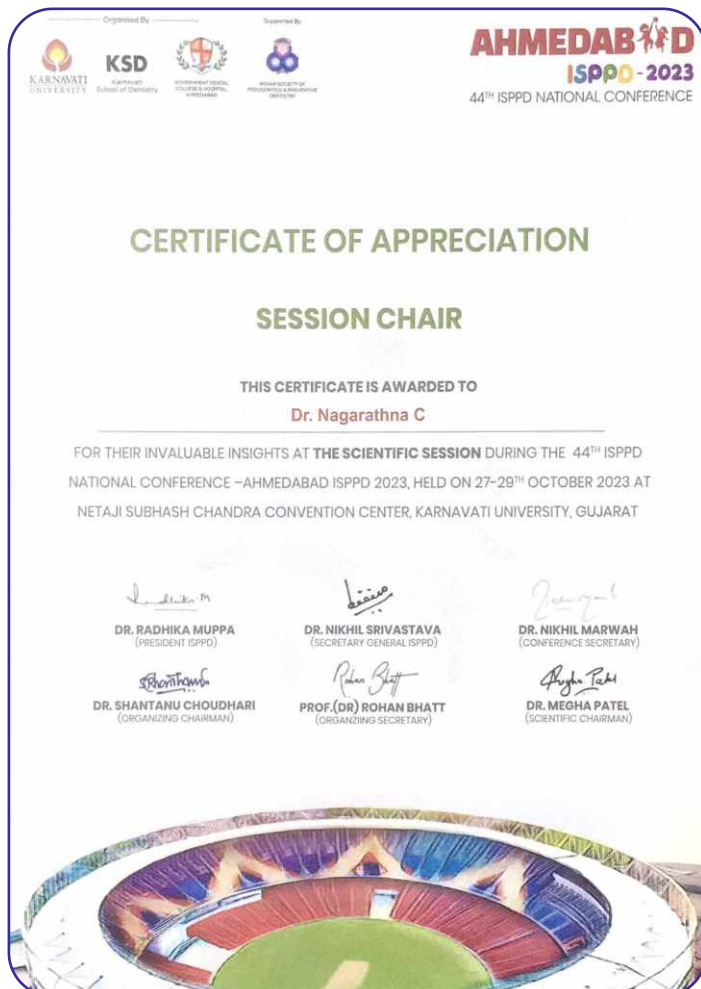INVITED LECTURES

DEPARTMENT OF PEDODONTICS AND PREVENTIVE DENTISTRY

1. Dr Nagarathna C – Professor

Chairperson for scientific presentations.

Date: 28.10.2023, 44th Annual ISPPD National Conference



OUTREACH PROGRAM

DEPARTMENT OF PUBLIC HEALTH DENTISTRY

Sl. No.	Date	Place of Camp conducted
1.	05/10/2023	Vaniyambadi, Tamil Nadu
2.	06/10/2023	Alangayam , Tamil Nadu
3.	07/10/2023	Madanur, Tamil Nadu
4.	08/10/2023	Ambur, Tamil Nadu
5.	27/10/2023	Nirashritara Parihara Kendra

OPD STATISTICS

DEPARTMENT OF ORAL MEDICINE AND RADIOLOGY

New cases	Old cases	Total cases	Patients per day
5171	5133	10304	565

SPECIAL CASE STATISTICS:

	Total number of cases
Pulpal And Periapical Diseases, Space Infections	660
Gingival and Periodontal Diseases	343
Mucosal Lesions, Oral Potentially Malignant Disorders, Malignancy	45
Trauma Cases	21

	Total number of cases
Bone Pathologies	01
Salivary Gland Diseases	04
Temporomandibular Diseases, Neuralgias and Muscle Diseases	09
Growths And Benign Conditions	01
Congenital Disorders	11

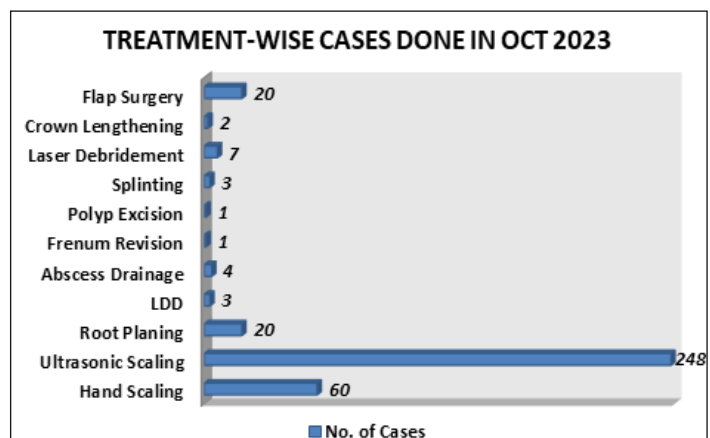
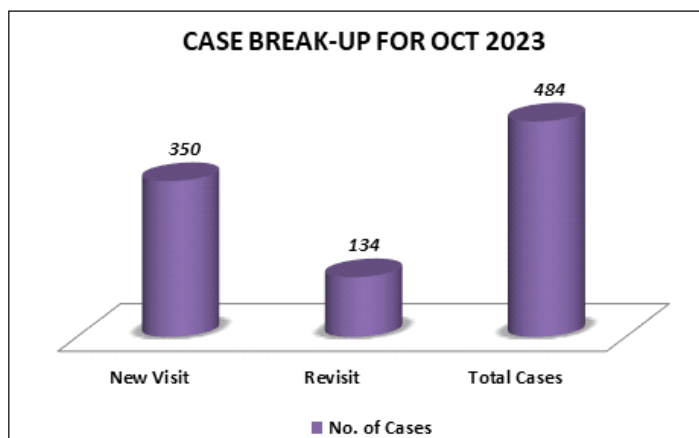
DEPARTMENT OF PROSTHODONTICS CROWN AND BRIDGE

Total no of working days:	Total no of Cases treated:	New	Revisited
18	948	295	653

DEPARTMENT OF ORAL AND MAXILLOFACIAL SURGERY

Total Cases	PG Cases	UG Cases	Major OT
1800	875	837	2

DEPARTMENT OF PERIODONTOLOGY



OPD STATISTICS**DEPARTMENT OF PEDODONTICS AND PREVENTIVE DENTISTRY**

	OCT
Total	1090
Scaling	95
Topical fluoride	72
Pit and fissure sealants	100
G.I.C.	106
Amalgam	09
Composite	62
I.P.C	14
D.P.C	11
Pulp Therapy	60

RCT	52
Extraction	105
Space Maintainer	20
Minor orthodontics	03
Apexification	04
Stainless steel crown- Primary	50
Stainless steel crown- Permanent	16
Strip Crowns	09
Traumatic Injuries splinting	02
Minor surgical procedures	03

DEPARTMENT OF CONSERVATIVE DENTISTRY AND ENDODONTICS**STATISTICS FOR THE YEAR 2023**

MONTH	TOTAL NO OF CASES	AMALGAM	COMPOSITE	GIC	TF
OCTOBER	110	39	16	21	34

UG STATISTICS FOR THE YEAR 2023

MONTH	No of working days	New visit	Re visit	Total	Average
OCTOBER	17	862	721	1583	93

PG STATISTICS FOR THE YEAR 2023

MONTH	TOTAL NO OF CASES	AMAL GAM	COMP OSITE	GIC	RCT	CROWN	P&C	INLAY	ONLAY	SURGERY
OCTOBER	423	06	61	23	173	11	07	00	00	00

DEPARTMENT OF ORTHODONTICS AND DENTOFACIAL ORTHOPEDICS

MONTH	OPD		TOTAL
	NEW	REVISIT	
OCTOBER 2023	605	978	1583

OPD STATISTICS

DEPARTMENT OF PUBLIC HEALTH DENTISTRY

FROM OUTDOOR ACTIVITIES

MONTH	NO. OF DENTAL CAMPS	DENTAL CAMPS- NO OF CASES	PRIMARY HEALTH CENTER (URBAN) Chunchunkuppe	PRIMARY HEALTH CENTER (URBAN) Channasandra	TOTAL NO OF CASES IN CAMPS
OCTOBER	5	625	74	95	794

OPD OCTOBER MONTH STATISTICS

MONTH	TOTAL NO OF CASES
OCTOBER	149

TREATMENT WISE PATIENT STATISTICS FOR THE MONTH OF OCTOBER 2023

SL.NO	TREATMENT DONE	NUMBER OF PATIENTS
1.	Extraction	1
2.	Restoration	5
3.	Oral prophylaxis	74
4.	Pit and fissure sealant	03
5.	Fluoride	01
6.	Health Education	109
7.	Tobacco cessation counselling	17
	TOTAL	210

DEPARTMENT OF IMPLANTOLOGY

STATISTICS FOR THE MONTH OF OCTOBER 2023

MONTH	IMPLANT	OPD	PROSTHETIC	FAIL IMPLANT
OCTOBER	15	30	47	NIL

DEPARTMENT OF ORAL PATHOLOGY

OPD OCTOBER MONTH STATISTICS : 420

Student Corner



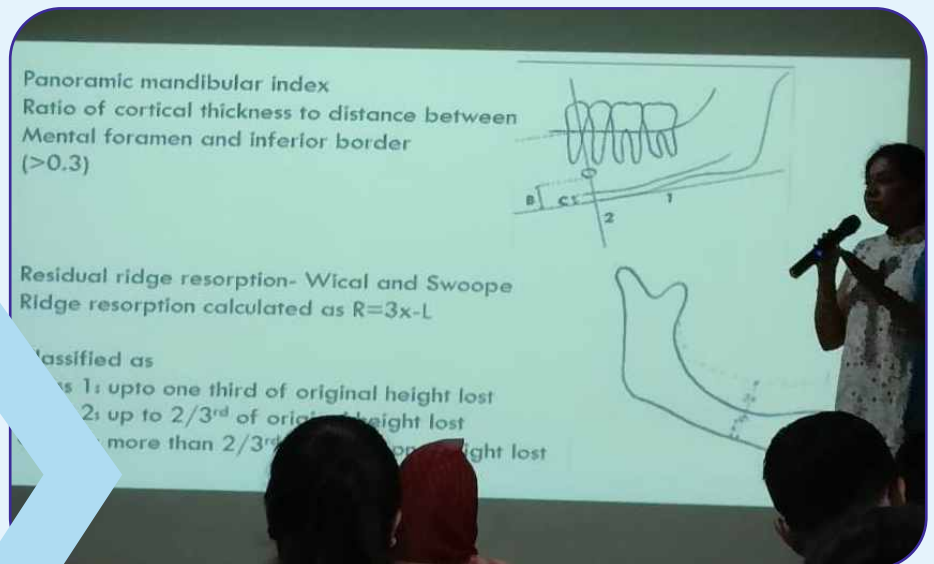
DEPARTMENT OF ORAL MEDICINE AND RADIOLOGY

EXPERIENCE SHARED BY A NEW INTERN, (TRANSFERRED FROM OTHER COLLEGE)

Embarking on my new internship programme in the department of **Oral Medicine and Radiology** at **RajaRajeswari Dental College and Hospital** has been an enriching and dynamic experience. Immersing in the intricacies of oral health diagnostics and treatment planning, everyday has been an opportunity to delve into a diverse array of cases. The supportive environment, coupled with the guidance of experienced professionals, has allowed me to bridge the gap between theoretical knowledge and practical application. From conducting detailed patient examination to interpreting diagnostic findings, each day presents with a new challenge and a chance to refine my skills. Collaborating with my colleagues in the department has not only expanded my clinical knowledge but has also fostered a sense of camaraderie. As I navigate through this professional journey, I am gaining insights that extend beyond textbooks shaping me into a more confident and capable dentist.

DEPARTMENT OF PROSTHODONTICS CROWN AND BRIDGE

1st Year Postgraduate master class organized by IPS Bangalore Branch, in association with KLE Dental College & Hospital, Bangalore



PATIENT FEEDBACK

DEPARTMENT OF ORAL MEDICINE AND RADIOLOGY

5 patients' feedbacks were collected and all were positive regarding the services offered by the department.

DEPARTMENT OF PERIODONTOLOGY

DEPARTMENT OF PERIODONTOLOGY
PATIENT FEEDBACK

To provide patient friendly facilities in the hospital, we need your valuable feedback & suggestions.

Name of Patient : Gautham
Age/Gender : 27/M
Address : Kengeri
Phone No : 9962764221
OP No : 2310040270
Email ID :

How do you rate the information given at the Reception Counter?
☐ Excellent ☒ Good ☐ Average ☐ Poor

How do you rate your reception by oral health care providers during your first visit as a patient?
☐ Excellent ☒ Good ☐ Average ☐ Poor

How do you rate the overall cleanliness of the department and the facilities provided?
☒ Excellent ☐ Good ☐ Average ☐ Poor

How do you rate your experience during a subsequent visit to the department?
☐ Excellent ☐ Good ☐ Average ☐ Poor

How do you rate the treatment services provided at the department?
☐ Excellent ☒ Good ☐ Average ☐ Poor

How do you rate the emergency treatment services at the hospital?
☐ Excellent ☒ Good ☐ Average ☐ Poor ☐ Not availed

How do you rate the treatment charges at this hospital?
☒ Excellent ☐ Good ☐ Average ☐ Poor

What is your overall opinion about the hospital?
☒ Excellent ☐ Good ☐ Average ☐ Poor

Suggestions (if any)

Signature of Patient Gautham 1 Date: 7/10/2023

DEPARTMENT OF PERIODONTOLOGY
PATIENT FEEDBACK

To provide patient friendly facilities in the hospital, we need your valuable feedback & suggestions.

Name of Patient : Varalakshmi
Age/Gender : 40/F
Address : Digunup, Bree Gandada Kavalu
Phone No : 9781472618
OP No : 2310110051
Email ID :

How do you rate the information given at the Reception Counter?
☐ Excellent ☒ Good ☐ Average ☐ Poor

How do you rate your reception by oral health care providers during your first visit as a patient?
☐ Excellent ☒ Good ☐ Average ☐ Poor

How do you rate the overall cleanliness of the department and the facilities provided?
☐ Excellent ☒ Good ☐ Average ☐ Poor

How do you rate your experience during a subsequent visit to the department?
☒ Excellent ☐ Good ☐ Average ☐ Poor

How do you rate the treatment services provided at the department?
☒ Excellent ☐ Good ☐ Average ☐ Poor

How do you rate the emergency treatment services at the hospital?
☐ Excellent ☒ Good ☐ Average ☐ Poor ☐ Not availed

How do you rate the treatment charges at this hospital?
☐ Excellent ☒ Good ☐ Average ☐ Poor

What is your overall opinion about the hospital?
☐ Excellent ☒ Good ☐ Average ☐ Poor

Suggestions (if any)

Signature of Patient Varalakshmi 2 Date: 12/10/23

DEPARTMENT OF PERIODONTOLOGY
PATIENT FEEDBACK

To provide patient friendly facilities in the hospital, we need your valuable feedback & suggestions.

Name of Patient : Nagaraju
Age/Gender : 35/M
Address : Bidadi
Phone No : 9945829980
OP No : 230515026
Email ID :

How do you rate the information given at the Reception Counter?
☐ Excellent ☒ Good ☐ Average ☐ Poor

How do you rate your reception by oral health care providers during your first visit as a patient?
☒ Excellent ☐ Good ☐ Average ☐ Poor

How do you rate the overall cleanliness of the department and the facilities provided?
☒ Excellent ☐ Good ☐ Average ☐ Poor

How do you rate your experience during a subsequent visit to the department?
☐ Excellent ☒ Good ☐ Average ☐ Poor

How do you rate the treatment services provided at the department?
☒ Excellent ☐ Good ☐ Average ☐ Poor

How do you rate the emergency treatment services at the hospital?
☐ Excellent ☒ Good ☐ Average ☐ Poor ☐ Not availed

How do you rate the treatment charges at this hospital?
☒ Excellent ☐ Good ☐ Average ☐ Poor

What is your overall opinion about the hospital?
☐ Excellent ☒ Good ☐ Average ☐ Poor

Suggestions (if any)

Signature of Patient Nagaraju 4 Date: 12/10/23

DEPARTMENT OF PERIODONTOLOGY
PATIENT FEEDBACK

To provide patient friendly facilities in the hospital, we need your valuable feedback & suggestions.

Name of Patient : Niganma
Age/Gender : 62/F
Address : Komagallu
Phone No : 7349542136
OP No : 231008079
Email ID :

How do you rate the information given at the Reception Counter?
☐ Excellent ☒ Good ☐ Average ☐ Poor

How do you rate your reception by oral health care providers during your first visit as a patient?
☐ Excellent ☒ Good ☐ Average ☐ Poor

How do you rate the overall cleanliness of the department and the facilities provided?
☒ Excellent ☐ Good ☐ Average ☐ Poor

How do you rate your experience during a subsequent visit to the department?
☐ Excellent ☒ Good ☐ Average ☐ Poor

How do you rate the treatment services provided at the department?
☐ Excellent ☒ Good ☐ Average ☐ Poor

How do you rate the emergency treatment services at the hospital?
☐ Excellent ☒ Good ☐ Average ☐ Poor ☐ Not availed

How do you rate the treatment charges at this hospital?
☒ Excellent ☐ Good ☐ Average ☐ Poor

What is your overall opinion about the hospital?
☐ Excellent ☒ Good ☐ Average ☐ Poor

Suggestions (if any)

Signature of Patient Niganma 3 Date: 3/10/2023

DEPARTMENT OF PEDODONTICS AND PREVENTIVE DENTISTRY

DEPARTMENT OF PEDIATRIC AND PREVENTIVE DENTISTRY

OUT PATIENT FEEDBACK FROM

NAME: Hansika Gowda DATE: 16/10/23
 AGE/SEX: 8y/M OP REGIST NO: 69929
 CONTACT NO: 9786646548

RATE YOUR EXPERIENCE WITH THE FOLLOWING ASPECTS OF YOUR VISIT

TITLE	VERY GOOD	GOOD	FAIR	POOR
RECEPTIONIST DESK				
EASE OF APPOINTMENT				
TREATMENT DONE				
TREATING DOCTOR				

OVER ALL SATISFACTION:

VERY SATISFACTORY / SATISFIED / UN SATISFIED

SIGNATURE OF PATIENT

DEPARTMENT OF PEDIATRIC AND PREVENTIVE DENTISTRY

OUT PATIENT FEEDBACK FROM

NAME: Taruna Unnik DATE: 12/10/23
 AGE/SEX: 10 Years / F OP REGIST NO: 2310120021
 CONTACT NO: 9652977421

RATE YOUR EXPERIENCE WITH THE FOLLOWING ASPECTS OF YOUR VISIT

TITLE	VERY GOOD	GOOD	FAIR	POOR
RECEPTIONIST DESK				
EASE OF APPOINTMENT				
TREATMENT DONE				
TREATING DOCTOR				

OVER ALL SATISFACTION:

VERY SATISFACTORY / SATISFIED / UN SATISFIED

SIGNATURE OF PATIENT

DEPARTMENT OF PEDIATRIC AND PREVENTIVE DENTISTRY

OUT PATIENT FEEDBACK FROM

NAME: Hansika Gowda DATE: 4/10/23
 AGE/SEX: 7/M OP REGIST NO: 2310040292
 CONTACT NO: 9745293928

RATE YOUR EXPERIENCE WITH THE FOLLOWING ASPECTS OF YOUR VISIT

TITLE	VERY GOOD	GOOD	FAIR	POOR
RECEPTIONIST DESK				
EASE OF APPOINTMENT				
TREATMENT DONE				
TREATING DOCTOR				

OVER ALL SATISFACTION:

VERY SATISFACTORY / SATISFIED / UN SATISFIED

SIGNATURE OF PATIENT

DEPARTMENT OF PEDIATRIC AND PREVENTIVE DENTISTRY

OUT PATIENT FEEDBACK FROM

NAME: Kemali C DATE: 17/10/23
 AGE/SEX: 9/M OP REGIST NO: 2310170332
 CONTACT NO: 9620909190

RATE YOUR EXPERIENCE WITH THE FOLLOWING ASPECTS OF YOUR VISIT

TITLE	VERY GOOD	GOOD	FAIR	POOR
RECEPTIONIST DESK				
EASE OF APPOINTMENT				
TREATMENT DONE				
TREATING DOCTOR				

OVER ALL SATISFACTION:

VERY SATISFACTORY / SATISFIED / UN SATISFIED

SIGNATURE OF PATIENT

DEPARTMENT OF PEDIATRIC AND PREVENTIVE DENTISTRY

OUT PATIENT FEEDBACK FROM

NAME: Vedha Arjun Gowda DATE: 08/10/23
 AGE/SEX: 7/M OP REGIST NO: 230920260
 CONTACT NO: 8214052160

RATE YOUR EXPERIENCE WITH THE FOLLOWING ASPECTS OF YOUR VISIT

TITLE	VERY GOOD	GOOD	FAIR	POOR
RECEPTIONIST DESK				
EASE OF APPOINTMENT				
TREATMENT DONE				
TREATING DOCTOR				

OVER ALL SATISFACTION:

VERY SATISFACTORY / SATISFIED / UN SATISFIED

SIGNATURE OF PATIENT

DEPARTMENT OF PROSTHODONTICS CROWN AND BRIDGE

PATIENT COMPLAINTS / FEEDBACK FORM

NAME: Kanish V Date: 09/11/2023
 AGE/SEX: Male / 33
 OP REGISTRATION NUMBER:
 CONTACT NUMBER: 9830962169
 NATURE OF COMPLAINT: Teeth implantation

NATURE OF FEEDBACK: I have very explanation and peaceful environment. The doctors have make sure that we are comfortable and we get best treatment and that too as soon as possible

Thank you Dr. Kunal and Dr. Manisha for such a great job work

SIGNATURE OF PATIENT

DEPARTMENT OF PEDIATRIC AND PREVENTIVE DENTISTRY

OUT PATIENT FEEDBACK FROM

NAME: Vishal Kumar DATE: 12/10/23
 AGE/SEX: 10/M OP REGIST NO: 2310120064
 CONTACT NO: 9001093103

RATE YOUR EXPERIENCE WITH THE FOLLOWING ASPECTS OF YOUR VISIT

TITLE	VERY GOOD	GOOD	FAIR	POOR
RECEPTIONIST DESK				
EASE OF APPOINTMENT				
TREATMENT DONE				
TREATING DOCTOR				

OVER ALL SATISFACTION:

VERY SATISFACTORY / SATISFIED / UN SATISFIED

SIGNATURE OF PATIENT

DEPARTMENT OF CONSERVATIVE DENTISTRY AND ENDODONTICS



DEPARTMENT OF CONSERVATIVE DENTISTRY AND ENDODONTICS

PATIENT FEEDBACK

To provide patient friendly facilities in the hospital, we need your valuable feedback & suggestions.

Name of Patient : Naguna
Age/Gender : 21/M
Address : Kumbalagode
Phone No : 879237994
OP No : 2309190261
Email ID : -

How do you rate the information given at the Reception Counter?
☐ Excellent ☒ Good ☐ Average ☐ Poor

How do you rate your reception by oral health care providers during your first visit as a patient?
☐ Excellent ☒ Good ☐ Average ☐ Poor

How do you rate the overall cleanliness of the department and the facilities provided?
☐ Excellent ☒ Good ☐ Average ☐ Poor

How do you rate your experience during a subsequent visit to the department?
☐ Excellent ☐ Good ☒ Average ☐ Poor

How do you rate the treatment services provided at the department?
☐ Excellent ☒ Good ☐ Average ☐ Poor

How do you rate the emergency treatment services at the hospital?
☒ Excellent ☐ Good ☐ Average ☐ Poor ☐ Not availed

How do you rate the treatment charges at this hospital?
☐ Excellent ☒ Good ☐ Average ☐ Poor

What is your overall opinion about the hospital?
☐ Excellent ☒ Good ☐ Average ☐ Poor

Suggestions (if any)

Naguna
Signature of Patient

Date: 6/10/23



DEPARTMENT OF CONSERVATIVE DENTISTRY AND ENDODONTICS

PATIENT FEEDBACK

To provide patient friendly facilities in the hospital, we need your valuable feedback & suggestions.

Name of Patient : Yamuna
Age/Gender : 50/Female
Address : Kamsa Kshipalya Bangalore
Phone No : 9606743587
OP No : 2307110195
Email ID : -

How do you rate the information given at the Reception Counter?
☒ Excellent ☐ Good ☐ Average ☐ Poor

How do you rate your reception by oral health care providers during your first visit as a patient?
☐ Excellent ☒ Good ☐ Average ☐ Poor

How do you rate the overall cleanliness of the department and the facilities provided?
☐ Excellent ☒ Good ☐ Average ☐ Poor

How do you rate your experience during a subsequent visit to the department?
☒ Excellent ☐ Good ☐ Average ☐ Poor

How do you rate the treatment services provided at the department?
☒ Excellent ☐ Good ☐ Average ☐ Poor

How do you rate the emergency treatment services at the hospital?
☐ Excellent ☒ Good ☐ Average ☐ Poor ☐ Not availed

How do you rate the treatment charges at this hospital?
☐ Excellent ☒ Good ☐ Average ☐ Poor

What is your overall opinion about the hospital?
☐ Excellent ☒ Good ☐ Average ☐ Poor

Suggestions (if any)

Yamuna
Signature of Patient

Date: 11-10-2023



DEPARTMENT OF CONSERVATIVE DENTISTRY AND ENDODONTICS

PATIENT FEEDBACK

To provide patient friendly facilities in the hospital, we need your valuable feedback & suggestions.

Name of Patient : Lakshmi
Age/Gender : 32/F
Address : Gollarsahally Bangalore
Phone No : 9742950236
OP No : 2309080262
Email ID : -

How do you rate the information given at the Reception Counter?
☐ Excellent ☒ Good ☐ Average ☐ Poor

How do you rate your reception by oral health care providers during your first visit as a patient?
☐ Excellent ☒ Good ☐ Average ☐ Poor

How do you rate the overall cleanliness of the department and the facilities provided?
☒ Excellent ☐ Good ☐ Average ☐ Poor

How do you rate your experience during a subsequent visit to the department?
☐ Excellent ☒ Good ☒ Average ☐ Poor

How do you rate the treatment services provided at the department?
☐ Excellent ☒ Good ☐ Average ☐ Poor

How do you rate the emergency treatment services at the hospital?
☐ Excellent ☐ Good ☒ Average ☐ Poor ☐ Not availed

How do you rate the treatment charges at this hospital?
☒ Excellent ☐ Good ☐ Average ☐ Poor

What is your overall opinion about the hospital?
☐ Excellent ☒ Good ☐ Average ☐ Poor

Suggestions (if any)

Lakshmi
Signature of Patient

Date: 21/10/23



DEPARTMENT OF CONSERVATIVE DENTISTRY AND ENDODONTICS

PATIENT FEEDBACK

To provide patient friendly facilities in the hospital, we need your valuable feedback & suggestions.

Name of Patient : Prakruthi
Age/Gender : 30/Female
Address : Bangalore, Ullal
Phone No : 9880743777
OP No : 2307260267
Email ID : -

How do you rate the information given at the Reception Counter?
☐ Excellent ☒ Good ☐ Average ☐ Poor

How do you rate your reception by oral health care providers during your first visit as a patient?
☐ Excellent ☒ Good ☐ Average ☐ Poor

How do you rate the overall cleanliness of the department and the facilities provided?
☐ Excellent ☒ Good ☐ Average ☐ Poor

How do you rate your experience during a subsequent visit to the department?
☐ Excellent ☒ Good ☐ Average ☐ Poor

How do you rate the treatment services provided at the department?
☐ Excellent ☒ Good ☐ Average ☐ Poor

How do you rate the emergency treatment services at the hospital?
☐ Excellent ☒ Good ☐ Average ☐ Poor ☐ Not availed

How do you rate the treatment charges at this hospital?
☐ Excellent ☒ Good ☐ Average ☐ Poor

What is your overall opinion about the hospital?
☐ Excellent ☒ Good ☐ Average ☐ Poor

Suggestions (if any)

Prakruthi
Signature of Patient

Date: 16/10/23

DEPARTMENT OF ORTHODONTICS AND DENTOFACIAL ORTHOPEDICS

RRDCH/NABH/ORTHO/07

Patient Complaints/ Feedback Form

Date- 21/10/2023

Name: Rashmitha
Age/sex: 21/F
Op Registration number: 2111160058
Contact number: 9037899442
Nature of complain:

Nature of feedback:
Doctor is very patient and she explains the work she is doing perfectly and gives the appointment very regularly. The treatment is going very smoothly and I am getting good positive results.

Rashmitha
Signature of patient

RRDCH/NABH/ORTHO/07

Patient Complaints/ Feedback Form

Date : 31/10/23.

Name: Tejaswini Gonda
Age/sex: 18/F
Op Registration number: 2107090003
Contact number: 6363624930
Nature of complain:

Nature of feedback: I am satisfied with the treatment at the college. Doctors here are very cooperative and understanding. I am visiting the college from one year for ortho treatment and I am happy with the treatment progress and with the conduct of the doctors.

Signature of patient
Tejaswini

DEPARTMENT OF IMPLANTOLOGY

PATIENT COMPLAINTS /FEEDBACK FORM

NAME: Abdul Razak Date: 03/10/23
AGE/SEX: 56/Male
OP REGISTRATION NUMBER: [REDACTED]
CONTACT NUMBER: [REDACTED]

NATURE OF COMPLAINT:
Missing teeth in lower arch, wants a fixed prosthesis.

NATURE OF FEEDBACK:
Treatment is very good, Dr. also very very friendly.

SIGNATURE OF PATIENT
Abdul Razak
3/10/23

PATIENT COMPLAINTS /FEEDBACK FORM

NAME: Dr. Uma. M Date: 12/10/23
AGE/SEX: 51/Female
OP REGISTRATION NUMBER: [REDACTED]
CONTACT NUMBER: [REDACTED]

NATURE OF COMPLAINT:
Brittle tooth (Lt) upper 1st molar. Extraction & Implant.

NATURE OF FEEDBACK:
Good. All P.G.s. (Past & present) & All Profs of Implantology Dept. } Thanks

SIGNATURE OF PATIENT
Uma M
12/10/23



RajaRajeswari Dental College and Hospital, Bengaluru

14, Ramohalli Cross, Mysore Road, Bengaluru-560074. KARNATAKA. Phone: 080 28437150, Fax: 080 28437468.

E-mail: principalrrdch@gmail.com www.rrdch.org www.rrdch.edu.in