



DECEMBER 2023 EDITION

# RajaRajeswari Dental College & Hospital

## NEWSLETTER



DEPARTMENT OF PEDODONTICS AND PREVENTIVE DENTISTRY

### CHRISTMAS CELEBRATION 2023



DEPARTMENT OF PUBLIC HEALTH DENTISTRY

### WORLD AIDS DAY- 1st December 2023



DISTRIBUTION OF RED RIBBON TO ALL THE FACULTY OF RRDCH



### EVENT ORGANISED:

1. Red ribbon campaign and sensitization of the staff of RRDCH
2. Pledge taken by staff and NSS volunteers
3. Awareness lecture by **Dr Raghavendra BM (Associate Professor, BMCRI Bangalore)**

**Objective of the event:** The NSS unit in association with Department of Public Health Dentistry of Rajarajeshwari Dental College and Hospital organised the above mentioned events on the occasion of WORLD AIDS DAY

### BRIEF OUTLINE OF THE EVENT:

- The day was kicked off by distribution of red ribbon to all the teaching and non teaching staff in the college.
- The programme started with a solemn oath taking ceremony at our college led by the distinguished Dean Dr Edwin Dewadoss in the presence of Chief Guest Dr Raghavendra BN , staff and NSS volunteers . As we stood united in this endeavor, the oath-taking ceremony served as a powerful moment, symbolizing our dedication to promoting education, empathy, and prevention in the face of this global health challenge.
- A lecture was rendered by **Dr Raghavendra BN (Associate Prof, Department of General Medicine)** who emphasised the paramount importance and our collective commitment to raising awareness about HIV/AIDS and fostering a supportive community.



OATH TAKING CEREMONY

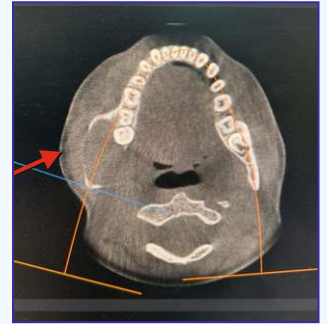
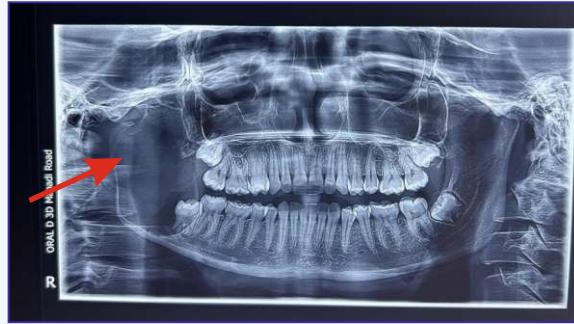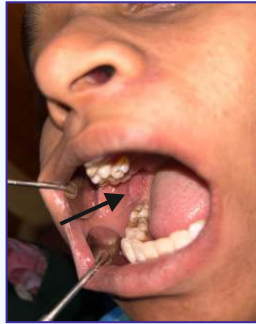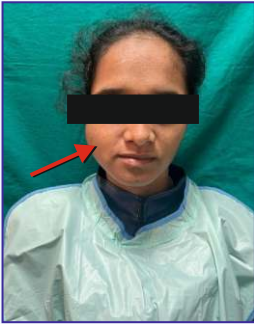AWARENESS LECTURE BY DR RAGHAVENDRA BM



## CASE OF THE MONTH

### DEPARTMENT OF ORAL MEDICINE AND RADIOLOGY

#### AMELOBLASTOMA INVOLVING RIGHT RAMUS AND ANGLE OF THE MANDIBLE

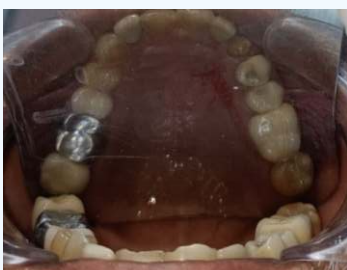

A female patient reported to the department with the complaint of swelling on the right side of face since 3 months. Swelling was initially small and gradually increased to the present size. On extraoral examination, a diffuse solitary swelling present on the right middle and lower third of face measuring about 5 x 5 cm was noted. Swelling was firm to hard in consistency with localised raise in temperature and tender on palpation. Paraesthesia present over right side of mandible. On intra oral examination, 48 was missing and expansion of cortical plate on pterygomandibular raphae region with yielding points & buccal vestibular tenderness over 47, 48 region was noted. Provisional diagnosis of dentigerous cyst i.r.t to 48 was given.

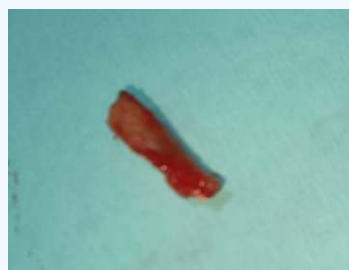Patient had an orthopantomogram which showed well defined unilocular radiolucency measuring about 8x6 cm involving right angle, ramus and extending till sigmoid notch, condyle, coronoid process. Thinning of medial and lateral cortical plate of mandible near angle and ramus region. Vertically impacted 48 which is below the occlusal plane of 47 with incomplete root formation, developing tooth buds i.r.t 18,28,38 present. CBCT was taken which revealed expansion of buccal cortical plate i.r.t 47, 48 region with loss of lingual cortical plate upto posterior border of ramus of mandible. Based on the clinical and radiographic findings, final diagnosis of Unilocular Ameloblastoma involving right ramus and angle of the mandible was given.

### DEPARTMENT OF PROSTHODONTICS CROWN AND BRIDGE

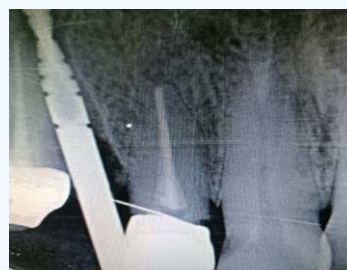#### AESTHETIC REHABILITATION OF MISSING CANINE USING SOCKET SHIELD TECHNIQUE



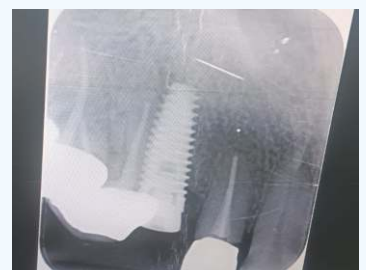Pre- operative photograph



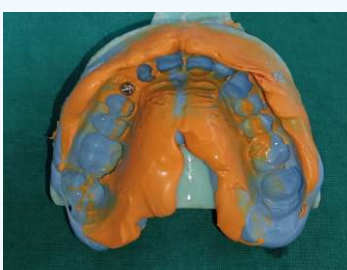Socket shielding done w.r.t 23



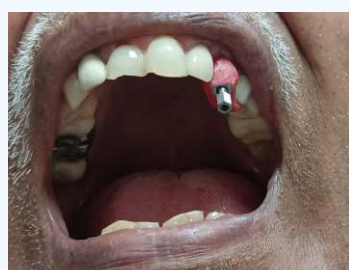Paralleling pin placed before placement of implant



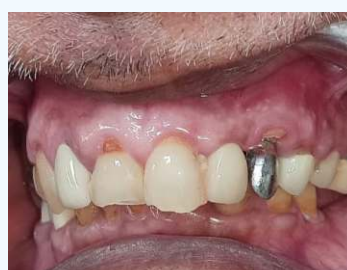Osseointegration after 3 months



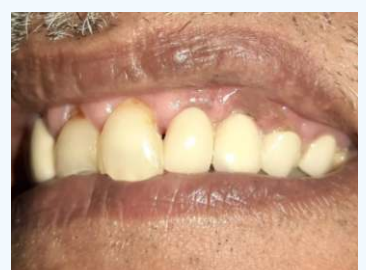Closed tray impression



Jig Trial



Metal Trial



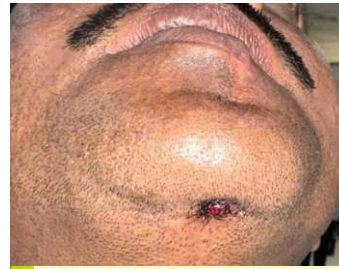Final prosthesis



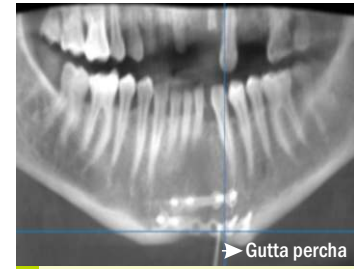
## DEPARTMENT OF ORAL AND MAXILLOFACIAL SURGERY

### CHRONIC MAXILLOFACIAL INFECTION (INFECTED MINIPLATE)

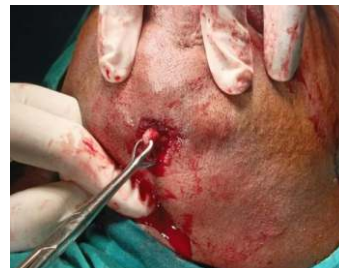A 40-year-old male patient reported to RRDCH with the complaint of recurrent pus discharge from the chin for past 8 months. Patient gave history of road traffic accident and had undergone treatment for the same. Clinical examination revealed an extra-oral fistula in the submental area with pus discharge. CBCT revealed the source of infection from the miniplates which was identified using a GP point. Patient was planned for fistula excision and plate removal under general anaesthesia. The intra oral site was closed with 3-0 vicryl. Oral hygiene was maintained using chlorhexidine irrigation. Postoperative medications were advised including antibiotics and analgesics. Sutures were removed after a week. Patient recovered with uneventful healing.



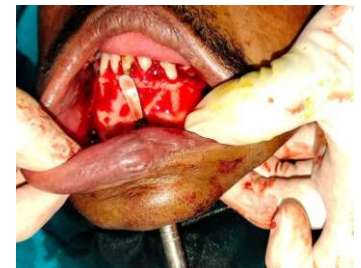Preoperative photo



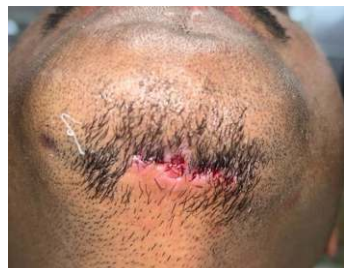Preoperative CBCT Scan



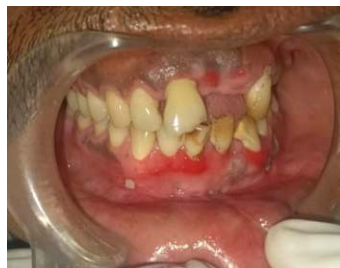Intra operative photo (fistula)



Intra operative photo (fistula excision allowing instrument to pass freely)



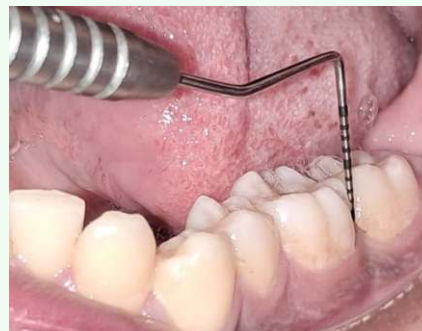Post operative photo



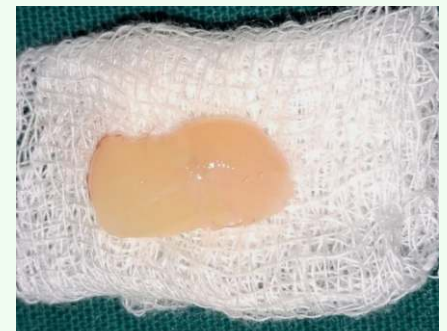## DEPARTMENT OF PERIODONTOLOGY

### LOCAL DRUG DELIVERY WITH ADVANCED PLATELET RICH FIBRIN

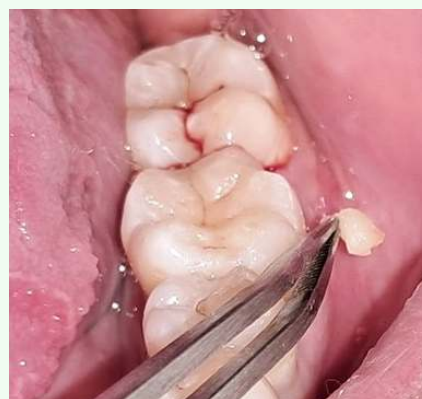Periodontitis is a polymicrobial disease which is initiated by dental plaque. Scaling and root planing remains the cornerstone of periodontal therapy. However, microorganisms can invade host tissues and may not be eliminated completely by mechanical therapy. Hence, LDD has been advocated to deliver the drug directly to the site of infection. A 31-year old male patient reported with the complaint of food lodgement in the left lower back tooth region since 3 months. On clinical examination, calculus was observed with probing pocket depth of 4-6 mm. Complete ultrasonic scaling was done with root planing followed by placement of advanced platelet rich fibrin with respect to 35, 36 & 37. Pocket depth was recorded at baseline and 1 month with reduction in pocket depth noted. Thus, advanced platelet rich fibrin can be used adjunctive to scaling and root planing for pocket reduction.



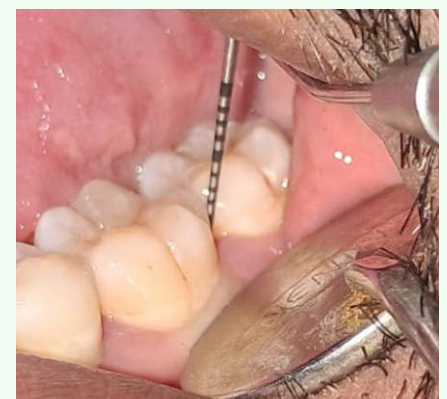1. Pre operative



2. Advanced platelet rich fibrin



3. Intra-operative



4. Post operative (1 month)

## DEPARTMENT OF PEDODONTICS AND PREVENTIVE DENTISTRY

### MANAGEMENT OF AN AVULSED PERMANENT ANTERIOR TOOTH IN A CHILD: A CASE REPORT

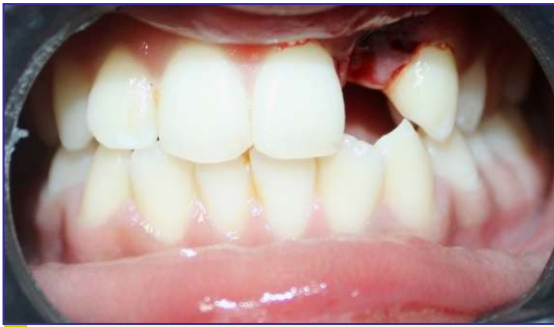

Figure 1 reveals avulsed tooth irt 22

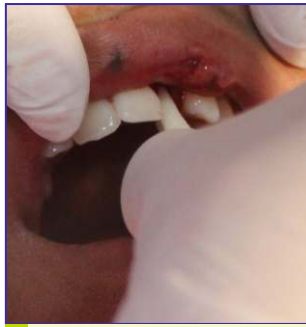

Figure 2 reveals successful replantation of avulsed tooth into socket

A 14-year-old male patient complained of knocked out tooth from upper front teeth region 60 minutes back. Patient gives a history of fall after a fight with his friend in the classroom in school followed by which the tooth 22 was avulsed. Patient gives history of bleeding from upper lip and upper front teeth region which stopped within 10 minutes of fall. No history of loss of consciousness, vomiting, seizures at the time of fall. Patient retrieved the avulsed tooth from the fallen site and stored it in pasteurized milk and arrived to our department.

Extra-oral examination showed presence of laceration of the upper lip.

Intra-oral clinical examination showed bleeding socket with gingival laceration irt 22, Enamel infraction irt 21.

Treatment plan: Replantation of the avulsed tooth was planned.

After saline irrigation of the socket, the avulsed tooth was cleaned and replanted using light digital pressure. Composite wire splinting done from 13 to 23. Post splinting radiograph was taken to confirm the tooth repositioning. Post operative instructions were given. Patient was recalled after 3 weeks, clinical and radiographic examination showed acceptable healing and the splint was removed. Pulp vitality test was carried out from teeth 13 to 23 and showed positive response irt 11,12,13,21, 33 and negative response irt 22. Multivisit root canal treatment was planned and carried out irt 22. Satisfactory healing was achieved and tooth was stabilized.

Figure 3 post-op radiograph of composite-wire splint

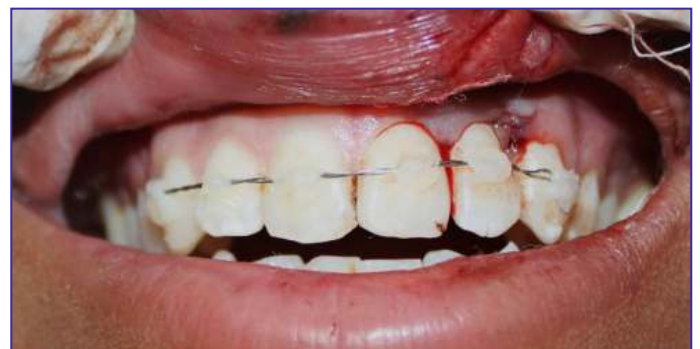
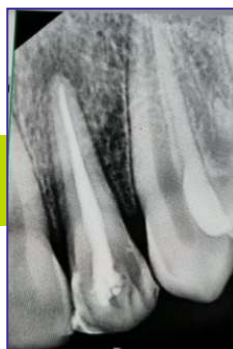
Figure 4 shows composite-wire splinting from 13 to 23

Figure 5 shows completion of Root Canal Treatment irt 22

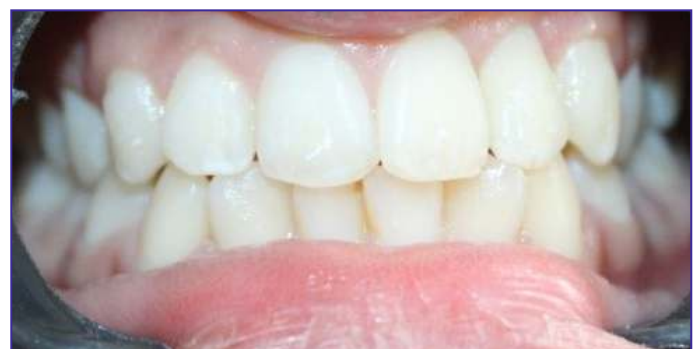
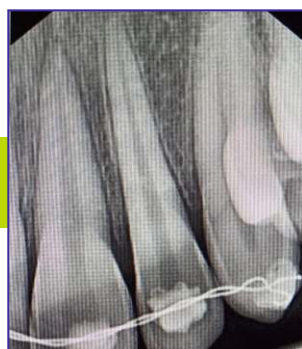
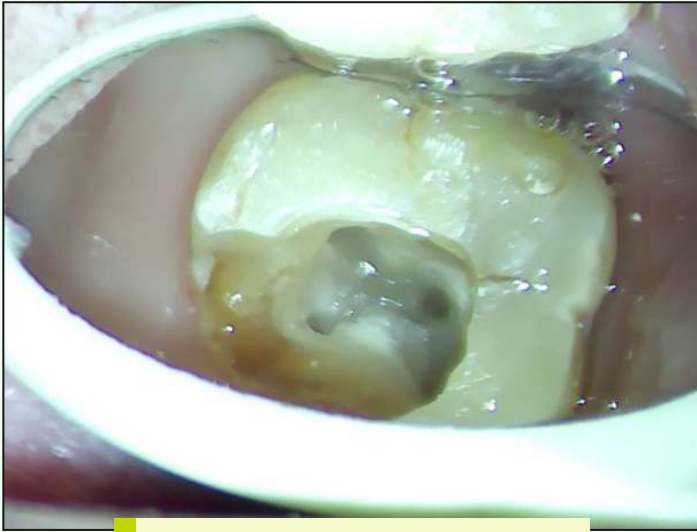Figure 6: Success of treatment is seen in the smile of the patient.

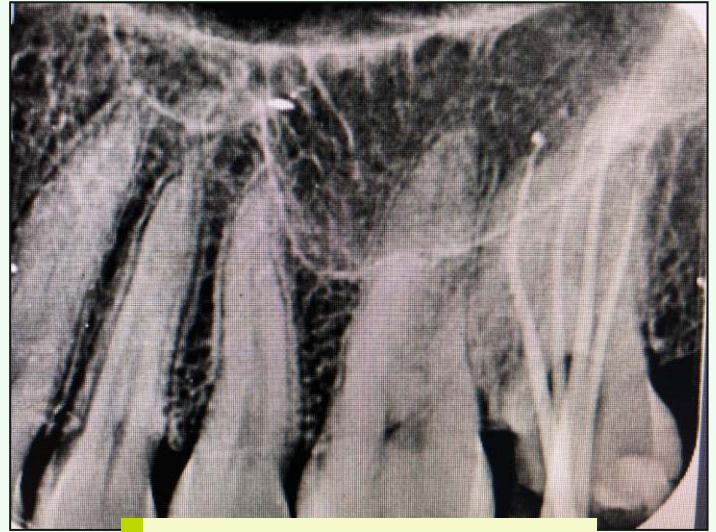

## DEPARTMENT OF CONSERVATIVE DENTISTRY AND ENDODONTICS

### MANAGEMENT OF MAXILLARY FIRST MOLAR WITH TWO PALATAL CANALS



ACCESS OPENING



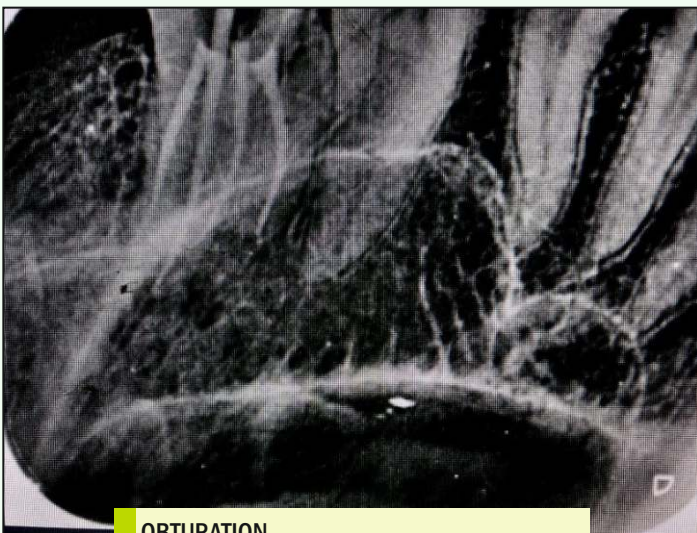
MASTER CONE

**Background:** Treatment of the entire root canal system is essential for the success of root canal treatment. Thus, it is necessary for the clinician to have knowledge of dental anatomy and its variations. There are several reports in literature which relate variations in number of palatal roots and canals in maxillary first molar. They describe the existence of either one palatal root with two canal or two separate palatal roots each with its own canal. The presence of additional canals in the palatal root of maxillary molars has been reported to be 2 to 5.1%. Although, the incidence of an extra canal in the palatal root is not high, it is important to take this variation into consideration during root canal therapy in order to ensure success. These extra canals must be identified and debrided to prevent endodontic failure.

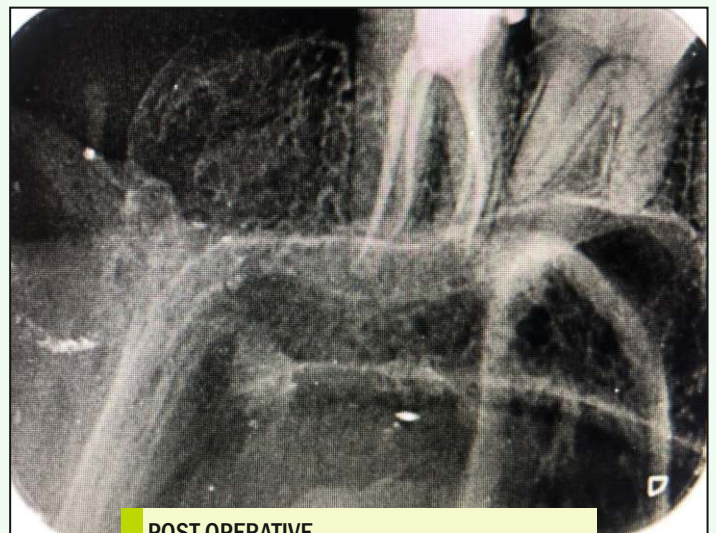
Even when the frequency of radicular anatomy abnormality is extremely low, dentists must consider the possibility that a tooth has extra root canals or even extra roots. This clinical case describes a maxillary molar with two palatal canals that appeared to unite in the apical third of the canal.

**Case Report :** A 30 year old patient reported to the department seeking treatment. Medical and Dental histories were not significant. Clinical examination revealed deep dental caries in mesial proximal side of 26 and tooth was tender on percussion. Radiographic examination revealed radiolucency involving enamel, dentin and pulp of 26. Hence, Root Canal Treatment was done.

**Conclusion:** Root Canal Treatment can be safely and reliably employed to treat such cases.



OBTURATION



POST OPERATIVE



## DEPARTMENT OF ORTHODONTICS AND DENTOFACIAL ORTHOPEDICS

### CASE REPORT

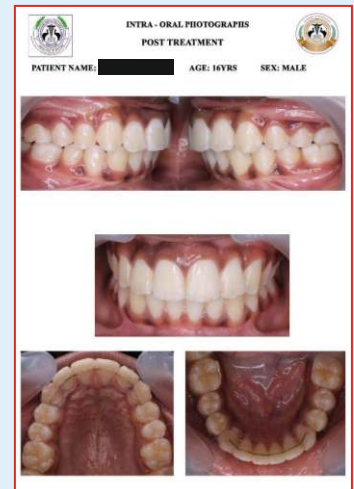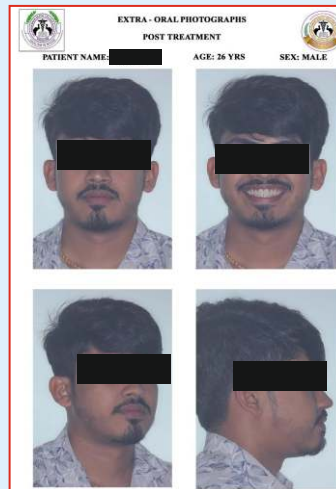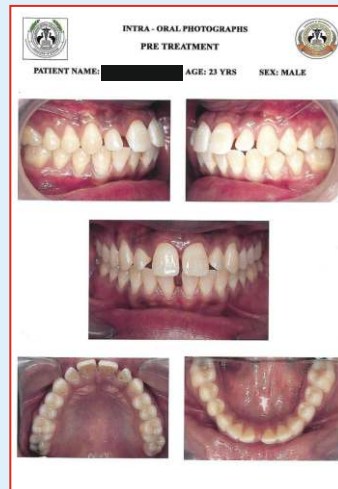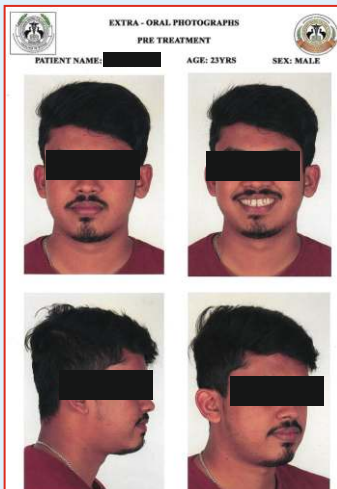NAME: N\*\*\*Z

AGE/SEX: 23/M

OP.NO: 2\*\*\*\*\*6

**CHIEF COMPLAINT:** Patient c/o spacing and forwardly placed upper and lower front teeth.

**PROBLEM LIST:** Angles Class I malocclusion.

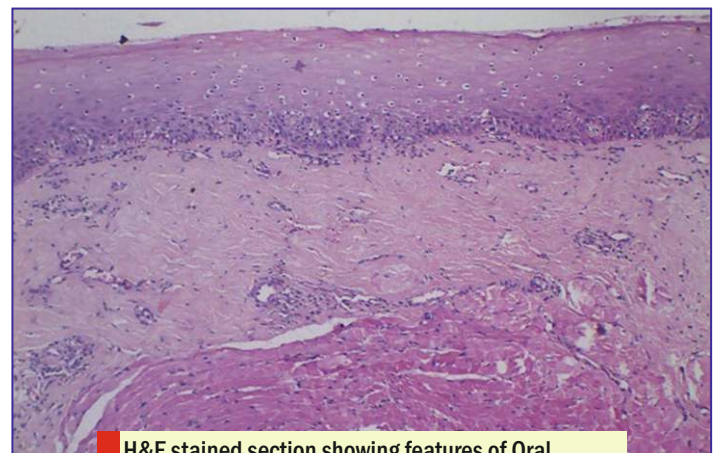
**TREATMENT PLAN:** Non-extraction line of treatment-MBT fixed appliance therapy


## DEPARTMENT OF ORAL PATHOLOGY

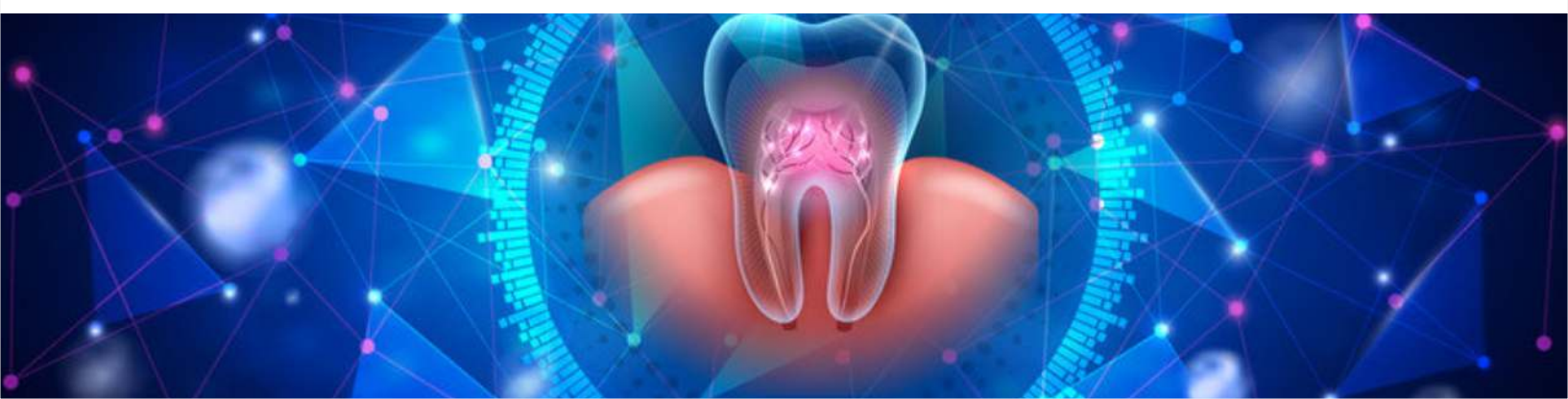
### ORAL SUBMUCOUS FIBROSIS

A 49 year old male patient came with a chief complaint of white patch on tongue since 6 years. On clinical examination irregular white patch measuring about 5cms was seen left lateral aspect of tongue.

Based on clinical findings a provisional diagnosis of leukoplakia was made. Incisional biopsy was taken and microscopic findings revealed a stratified squamous parakeratotic epithelium which was atrophied in certain areas with loss of rete ridges. The underlying connective tissue revealed dense bundles of collagen fibres merging with the muscle layer in the deeper connective tissue. Diffuse mild inflammatory infiltrate was seen. The histopathologic features were suggestive of Oral Sub mucous Fibrosis.



H&E stained section showing features of Oral Submucous fibrosis. (20x)



## PUBLICATIONS

Sl. No.	TITLE	JOURNAL & ISSUE	AUTHORSHIP
<b>DEPARTMENT OF ORAL MEDICINE AND RADIOLOGY</b>			
1.	Saliva as a diagnostic tool for glucose estimation in diabetic patients	Journal of Indian Academy of Oral Medicine and Radiology, 2023;35:527-31.	<ul style="list-style-type: none"> <li>• Dr Deepali Pandey</li> <li>• Dr Poornima C</li> <li>• Dr Balaji P</li> </ul>
2.	Association between Clinical diagnosis of Temporomandibular Disorders using Research Diagnostic Criteria and Morphological changes of the Condyle and Abnormal Joint spaces using CBCT.	Journal of Indian Academy of Oral Medicine and Radiology, 2023;35:577-82.	<ul style="list-style-type: none"> <li>• Dr Prarthana G A</li> </ul>
<b>DEPARTMENT OF PEDODONTICS AND PREVENTIVE DENTISTRY</b>			
1.	Choukroun's Autologous Platelet Concentrate Used in Immature Necrotic Tooth during Revascularization: A Clinical and Radiological Report of a Case	Journal of south asian association of pediatric dentist, Volume 67, Issue 3	<ul style="list-style-type: none"> <li>• Dr Umapathy Thimmegowda</li> <li>• Dr Nagarathna Chikkanarasaiah</li> </ul>

## BOOK PUBLICATIONS

Sl. No.	TITLE	PUBLISHER	ISSUE
<b>DEPARTMENT OF PROSTHODONTICS CROWN AND BRIDGE</b>			
1.	Viva Voce in 2nd BDS Dental Materials- Volume 1	Lambert	<ul style="list-style-type: none"> <li>• Dr Krishna Kumar</li> </ul>
2.	Viva Voce in 2nd BDS Dental Materials- Volume 2	Lambert	<ul style="list-style-type: none"> <li>• Dr Sindhu Sudhakar</li> <li>• Rayala Lokesh</li> </ul>





## DEPARTMENT OF PROSTHODONTICS CROWN AND BRIDGE

Device for early detection and prevention of oral cancer based on artificial intelligence-Design No: 6331404, Date of registration 16-12-2023-Registered for a UK Design



Intellectual  
Property  
Office

### Certificate of Registration for a UK Design

Design number: 6331404

Grant date: 16 December 2023

Registration date: 06 December 2023

**This is to certify that,**

in pursuance of and subject to the provision of Registered Designs Act 1949, the design of which a representation or specimen is attached, had been registered as of the date of registration shown above in the name of

Dr. Sri Lakshmi Jagadeesh, Dr. Yashkumar Dilipbhai Chauhan, Dr. Kirubavathy

Krishnamoorthy, Dr. Alok Sharma, Dr. Swati Sharma, Manav Kamlesh Kumar

Patel, Ms. Rohini Rakesh Jadhav, Mr. Anand Kumar, Dr. Umadevi Sankararajan,

Dr. Aditya Dilip Kumar Patil

in respect of the application of such design to:

Device for Early Detection and Prevention of Oral Cancer based on Artificial

Intelligence

International Design Classification:

Version: 14-2023

Class: 24 MEDICAL AND LABORATORY EQUIPMENT

Subclass: 01 APPARATUS AND EQUIPMENT FOR DOCTORS, HOSPITALS  
AND LABORATORIES

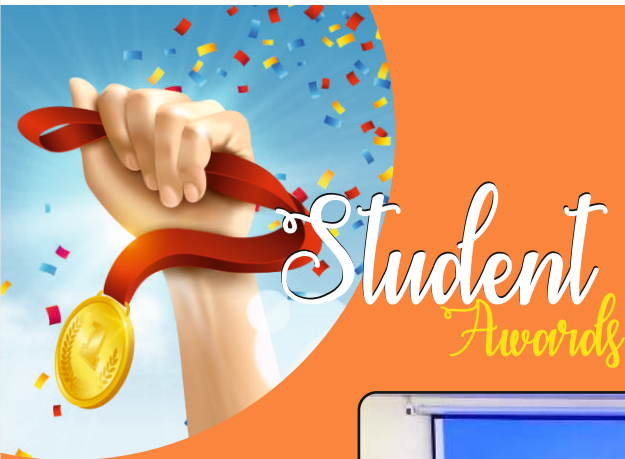**Adam Williams**

Comptroller-General of Patents, Designs and Trade Marks

Intellectual Property Office

The attention of the Proprietor(s) is drawn to the important notes overleaf.

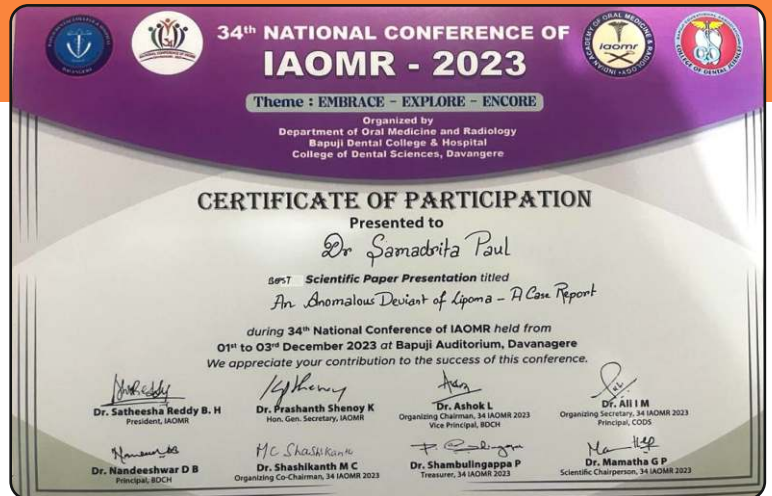



# Student Awards

## DEPARTMENT OF ORAL MEDICINE AND RADIOLOGY

Dr Samadrita Paul., Post graduate student of our department had been awarded with "Best Scientific Paper" titled "An Anomalous Deviant of Lipoma- A case report" in 34th IAOMR National Conference, held from 1st to 3rd December 2023 at Davanagere.

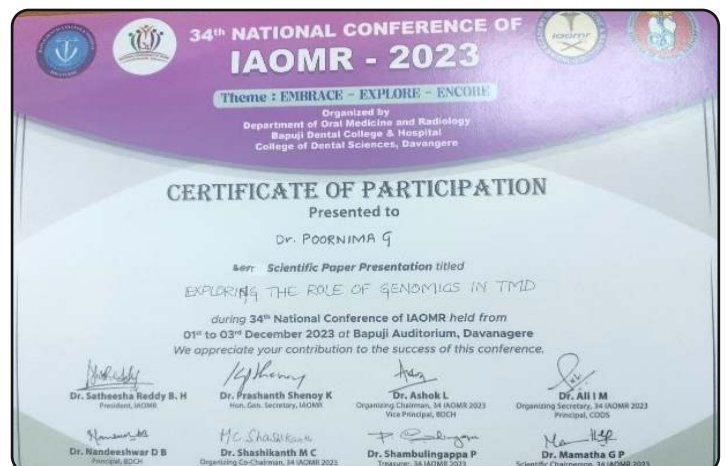

## DEPARTMENT OF PUBLIC HEALTH DENTISTRY

PROGRAM	PLACE	CONTEST	PARTICIPATION BY	PRIZE WON
49th Karnataka State, 8th Inter State IDA Conference	Manipal College of Dental Sciences, Mangalore	Poster Presentation	Dr. Rakshita	First Prize
49th Karnataka State, 8th Inter State IDA Conference	Manipal College of Dental Sciences, Mangalore	Poster Presentation	Dr. Lalitha Rani	First Prize

## FACULTY AWARDS

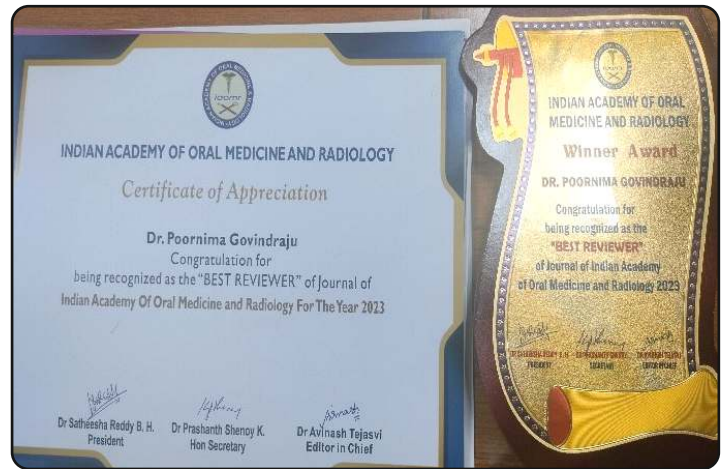## DEPARTMENT OF ORAL MEDICINE AND RADIOLOGY





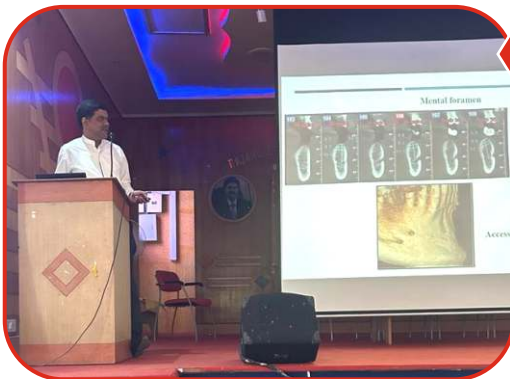Dr Poornima G., Professor had been awarded with “Best Scientific Paper” titled “Exploring the Role of Genomics in TMD” and also “Best Reviewer” of the Journal of Indian Academy of Oral Medicine and Radiology for the year 2023 in 34th IAOMR National Conference, held from 1st to 3rd December 2023 at Davanagere.

## FACULTY AWARDS



## INVITED LECTURES

### DEPARTMENT OF ORAL MEDICINE AND RADIOLOGY



Dr. Mahesh Kumar T.S., Professor, has delivered an Invited guest lecture on “CBCT in Implantology” at CDE program organized by RRDCH, Bengaluru, on 6th December 2023.

## OUTREACH PROGRAM

### DEPARTMENT OF PUBLIC HEALTH DENTISTRY

Sl. No.	DATE	PLACE OF CAMP CONDUCTED
1.	05/12/2023	Chunchunkuppe satellite centre & PHC Chandrappa circle, Bangalore
2.	09/12/2023 & 10/12/2023	Ambur, Tamil Nadu
3.	12/12/2023	Chunchunkuppe satellite centre & PHC Chandrappa circle, Bangalore
4.	15/12/2023	Nirashritara Parihara Kendra
5.	17/12/2023	Makali, Channapatna
6.	19/12/2023	Chunchunkuppe satellite centre & PHC Chandrappa circle, Bangalore
7.	20/12/2023	Ahamed Nagar, Nagarbhavi
8.	22/12/2023 & 23/12/2023	Ambur, Tamil Nadu

## OPD STATISTICS

## ▶ DEPARTMENT OF ORAL MEDICINE AND RADIOLOGY

New Cases	Old Cases	Total Cases	Patients per day
7010	7092	14102	522

## SPECIAL CASE STATISTICS:

	Total number of cases		Total number of cases
Pulpal And Periapical Diseases, Space Infections	785	Salivary Gland Diseases	01
Gingival and Periodontal Diseases	330	Temporomandibular Diseases, Neuralgias and Muscle Diseases	08
Mucosal Lesions, Oral Potentially Malignant Disorders, Malignancy	46	Benign growth and Conditions	03
Trauma Cases	14	Congenital Disorders	12
Bone Pathologies	08		

## DEPARTMENT SPECIFIC STATISTICS:

Space infection	16	Smoker's palate	04	Leukoplakia	08	Oral submucous fibrosis	10	Erosive Lichen Planus	03
Reticular Lichen Planus	01	Aphthous Ulcer	01	Smoker's melanosis	03	Frictional keratosis	06	Traumatic ulcer	02
Angular cheilitis	01	Anaemic stomatitis	02	Epulis fissuratum	01	Non healing ulcer	01	Carcinoma of GBS	01
Malignant growth	01	Lymphadenitis	01	Soft tissue injury	04	Fracture cases	10	Radicular cyst	04
Ameloblastoma	02	Periapical Cemento -Osseous Dysplasia	01	Palatal defect	01	Sialolithiasis	01	Myofascial pain	03
Disc displacement with reduction	04	Trigeminal neuralgia	01	Traumatic fibroma	02	Reactive hyperplasia	01	Hemangioma	01
Fluorosis	08	Partial Anodontia	03						

## ▶ DEPARTMENT OF PROSTHODONTICS CROWN AND BRIDGE

Total no of working days:	Total no of Cases treated:	New	Revisited
24	1308	391	917

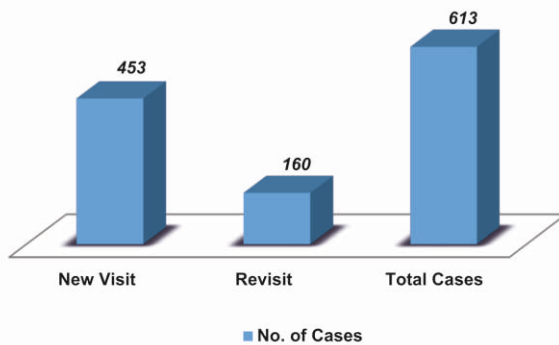
## ▶ DEPARTMENT OF ORAL AND MAXILLOFACIAL SURGERY

Total Cases	PG Cases	UG Cases	Major OT
1800	875	837	2

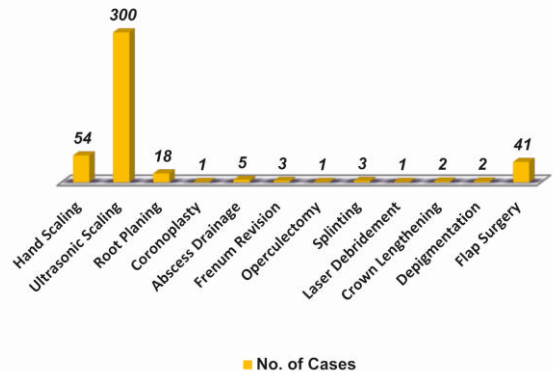


## DEPARTMENT OF PERIODONTOLOGY

CASE BREAK-UP FOR DEC 2023



TREATMENT-WISE CASES DONE IN DEC 2023



## DEPARTMENT OF PEDODONTICS AND PREVENTIVE DENTISTRY

DECEMBER	
Total	1663
Scaling	132
Topical fluoride	106
Pit and fissure sealants	142
G.I.C.	156
Amalgam	14
Composite	110
I.P.C	34
D.P.C	23
Pulp Therapy	104

RCT	80
Extraction	120
Space Maintainer	30
Minor orthodontics	10
Apexification	14
Stainless steel crown- Primary	86
Stainless steel crown- Permanent	32
Strip Crowns	16
Traumatic Injuries splinting	08
Minor surgical procedures	05

## DEPARTMENT OF CONSERVATIVE DENTISTRY AND ENDODONTICS

STATISTICS FOR THE YEAR 2023

MONTH	No of working days	New visit	Re visit	Total	Average
DECEMBER	24	1285	1033	2318	97

UG STATISTICS FOR THE YEAR 2023

MONTH	TOTAL NO OF CASES	AMALGAM	COMPOSITE	GIC	TF
DECEMBER	266	115	14	68	69

PG STATISTICS FOR THE YEAR 2023

MONTH	TOTAL NO OF CASES	AMALGAM	COMP OSITE	GIC	RCT	CROWN	P&C	INLAY	ONLAY	SURGERY
DECEMBER	568	00	90	44	235	12	00	01	00	00

**OPD STATISTICS****DEPARTMENT OF ORTHODONTICS AND DENTOFACIAL ORTHOPEDICS**

MONTH	OPD		TOTAL
	NEW	REVISIT	
DECEMBER 2023	882	1480	2362

**DEPARTMENT OF PUBLIC HEALTH DENTISTRY****FROM OUTDOOR ACTIVITIES**

MONTH	NO. OF DENTAL CAMPS	DENTAL CAMPS- NO OF CASES	PRIMARY HEALTH CENTER (URBAN) Chunchunkuppe	PRIMARY HEALTH CENTER (URBAN) Channasandra	TOTAL NO OF CASES IN CAMPS
DECEMBER	8	378	115	138	631

**OPD DECEMBER MONTH STATISTICS**

MONTH	TOTAL NO OF CASES
DECEMBER	189

**TREATMENT WISE PATIENT STATISTICS FOR THE MONTH OF DECEMBER 2023**

SL.NO	TREATMENT DONE	NUMBER OF PATIENTS
1.	Extraction	1
2.	Restoration	17
3.	Oral prophylaxis	85
4.	Pit and fissure sealant	2
5.	Fluoride	11
6.	Health Education	51
7.	Tobacco cessation counselling	44
	<b>TOTAL</b>	<b>211</b>

**DEPARTMENT OF ORAL IMPLANTOLOGY****STATISTICS FOR THE MONTH OF DECEMBER 2023**

MONTH	IMPLANT	OPD	PROSTHETIC	FAIL IMPLANT
DECEMBER	15	40	53	1

**DEPARTMENT OF ORAL PATHOLOGY**

OPD DECEMBER MONTH STATISTICS : 425

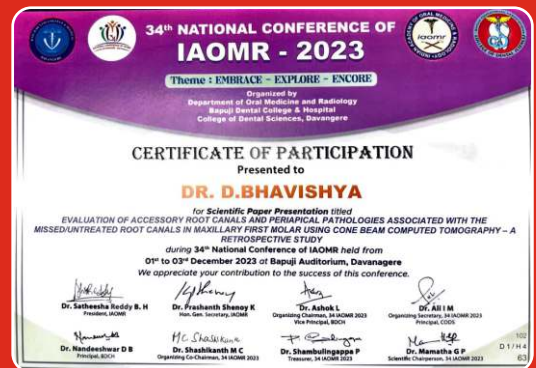

# Student Corner



## DEPARTMENT OF ORAL MEDICINE AND RADIOLOGY

Dr D Bhavishya., Post graduate student of our department had presented a scientific paper titled "Evaluation of accessory root canals and periapical pathologies associated with the missed/ untreated root canals in maxillary first molar using Cone beam computed tomography- A retrospective study" in 34th IAOMR National Conference, held from 1st to 3rd December 2023 at Davanagere.



## PATIENT FEEDBACK

### DEPARTMENT OF ORAL MEDICINE AND RADIOLOGY

21 patients' feedback were collected and all were positive regarding the services offered by the department.

### DEPARTMENT OF PROSTHODONTICS CROWN AND BRIDGE

#### PATIENT COMPLAINTS /FEEDBACK FORM

NAME: Suresh Date: 19/12/23

AGE/SEX: 64/M

OP REGISTRATION NUMBER: 2111240014

CONTACT NUMBER:

NATURE OF COMPLAINT:

Pt complains of missing teeth in the upper left front region of mouth.

NATURE OF FEEDBACK:

Good treatment done by Doctor.

SIGNATURE OF PATIENT

## DEPARTMENT OF PERIODONTOLOGY



### DEPARTMENT OF PERIODONTOLOGY

#### PATIENT FEEDBACK

To provide patient friendly facilities in the hospital, we need your valuable feedback & suggestions.

Name of Patient : MANISHA

Age/Gender : 28/F

Address : Kengeri

Phone No : 7232108210

OP No : 2312180313

Email ID :

How do you rate the information given at the Reception Counter?  
☒ Excellent ☐ Good ☐ Average ☐ Poor

How do you rate your reception by oral health care providers during your first visit as a patient?  
☒ Excellent ☐ Good ☐ Average ☐ Poor

How do you rate the overall cleanliness of the department and the facilities provided?  
☐ Excellent ☒ Good ☐ Average ☐ Poor

How do you rate your experience during a subsequent visit to the department?  
☒ Excellent ☐ Good ☐ Average ☐ Poor

How do you rate the treatment services provided at the department?  
☒ Excellent ☐ Good ☐ Average ☐ Poor

How do you rate the emergency treatment services at the hospital?  
☒ Excellent ☐ Good ☐ Average ☐ Poor ☐ Not availed

How do you rate the treatment charges at this hospital?  
☐ Excellent ☐ Good ☐ Average ☐ Poor

What is your overall opinion about the hospital?  
☒ Excellent ☐ Good ☐ Average ☐ Poor

Suggestions (if any)

Signature of Patient

Date: 18/12/23



### DEPARTMENT OF PERIODONTOLOGY

#### PATIENT FEEDBACK

To provide patient friendly facilities in the hospital, we need your valuable feedback & suggestions.

Name of Patient : LOKESH

Age/Gender : 35/M

Address : Bidadi

Phone No : 9842324480

OP No : 2312180309

Email ID :

How do you rate the information given at the Reception Counter?  
☒ Excellent ☐ Good ☐ Average ☐ Poor

How do you rate your reception by oral health care providers during your first visit as a patient?  
☒ Excellent ☐ Good ☐ Average ☐ Poor

How do you rate the overall cleanliness of the department and the facilities provided?  
☒ Excellent ☐ Good ☐ Average ☐ Poor

How do you rate your experience during a subsequent visit to the department?  
☒ Excellent ☐ Good ☐ Average ☐ Poor

How do you rate the treatment services provided at the department?  
☒ Excellent ☐ Good ☐ Average ☐ Poor

How do you rate the emergency treatment services at the hospital?  
☒ Excellent ☐ Good ☐ Average ☐ Poor ☐ Not availed

How do you rate the treatment charges at this hospital?  
☐ Excellent ☒ Good ☐ Average ☐ Poor

What is your overall opinion about the hospital?  
☐ Excellent ☒ Good ☐ Average ☐ Poor

Suggestions (if any)

Signature of Patient

Date: 20/12/23



### DEPARTMENT OF PERIODONTOLOGY

#### PATIENT FEEDBACK

To provide patient friendly facilities in the hospital, we need your valuable feedback & suggestions.

Name of Patient : SHYMA LAMN

Age/Gender : 40/F

Address : RAMOHALLI

Phone No : 9122367810

OP No : 230910033

Email ID :

How do you rate the information given at the Reception Counter?  
☐ Excellent ☒ Good ☐ Average ☐ Poor

How do you rate your reception by oral health care providers during your first visit as a patient?  
☐ Excellent ☒ Good ☐ Average ☐ Poor

How do you rate the overall cleanliness of the department and the facilities provided?  
☐ Excellent ☐ Good ☒ Average ☐ Poor

How do you rate your experience during a subsequent visit to the department?  
☐ Excellent ☒ Good ☐ Average ☐ Poor

How do you rate the treatment services provided at the department?  
☒ Excellent ☐ Good ☐ Average ☐ Poor

How do you rate the emergency treatment services at the hospital?  
☐ Excellent ☒ Good ☐ Average ☐ Poor ☐ Not availed

How do you rate the treatment charges at this hospital?  
☐ Excellent ☒ Good ☐ Average ☐ Poor

What is your overall opinion about the hospital?  
☐ Excellent ☒ Good ☐ Average ☐ Poor

Suggestions (if any)

Signature of Patient

Date: 13/12/23



### DEPARTMENT OF PERIODONTOLOGY

#### PATIENT FEEDBACK

To provide patient friendly facilities in the hospital, we need your valuable feedback & suggestions.

Name of Patient : SHRIDAPA

Age/Gender : 38/M

Address : Kubalgouda

Phone No : 923200490

OP No : 220620037

Email ID :

How do you rate the information given at the Reception Counter?  
☒ Excellent ☐ Good ☐ Average ☐ Poor

How do you rate your reception by oral health care providers during your first visit as a patient?  
☐ Excellent ☒ Good ☐ Average ☐ Poor

How do you rate the overall cleanliness of the department and the facilities provided?  
☐ Excellent ☒ Good ☐ Average ☐ Poor

How do you rate your experience during a subsequent visit to the department?  
☒ Excellent ☐ Good ☐ Average ☐ Poor

How do you rate the treatment services provided at the department?  
☐ Excellent ☒ Good ☐ Average ☐ Poor

How do you rate the emergency treatment services at the hospital?  
☐ Excellent ☒ Good ☐ Average ☐ Poor ☐ Not availed

How do you rate the treatment charges at this hospital?  
☐ Excellent ☒ Good ☐ Average ☐ Poor

What is your overall opinion about the hospital?  
☐ Excellent ☒ Good ☐ Average ☐ Poor

Suggestions (if any)

Signature of Patient

Date: 28/12/23



## DEPARTMENT OF PERIODONTOLOGY

**DEPARTMENT OF PERIODONTOLOGY**  
**PATIENT FEEDBACK**

To provide patient friendly facilities in the hospital, we need your valuable feedback & suggestions.

Name of Patient : PUSHPA  
Age/Gender : 29 Y/F  
Address :  
Phone No : 9812044143  
OP No : 23180989  
Email ID :

How do you rate the information given at the Reception Counter?  
☐ Excellent ☒ Good ☐ Average ☐ Poor

How do you rate your reception by oral health care providers during your first visit as a patient?  
☐ Excellent ☒ Good ☐ Average ☐ Poor

How do you rate the overall cleanliness of the department and the facilities provided?  
☐ Excellent ☐ Good ☒ Average ☐ Poor

How do you rate your experience during a subsequent visit to the department?  
☐ Excellent ☐ Good ☐ Average ☐ Poor

How do you rate the treatment services provided at the department?  
☐ Excellent ☒ Good ☐ Average ☐ Poor

How do you rate the emergency treatment services at the hospital?  
☐ Excellent ☐ Good ☒ Average ☐ Poor ☐ Not availed

How do you rate the treatment charges at this hospital?  
☐ Excellent ☐ Good ☒ Average ☐ Poor

What is your overall opinion about the hospital?  
☐ Excellent ☒ Good ☐ Average ☐ Poor

Suggestions (if any)

*[Signature]*  
Signature of Patient

Date: 5/12/23

## DEPARTMENT OF PEDODONTICS AND PREVENTIVE DENTISTRY

**DEPARTMENT OF PEDIATRIC AND PREVENTIVE DENTISTRY**  
**OUT PATIENT FEEDBACK FROM**

NAME: SAMRITHA DATE: 16/12/23  
AGE/SEX: 13/F OP REGIST NO: 2312160215  
CONTACT NO: 9686155683

RATE YOUR EXPERIENCE WITH THE FOLLOWING ASPECTS OF YOUR VISIT

TITLE	VERY GOOD	GOOD	FAIR	POOR
RECEPTIONIST DESK		<input checked="" type="checkbox"/>		
EASE OF APPOINTMENT		<input checked="" type="checkbox"/>		
TREATMENT DONE		<input checked="" type="checkbox"/>		
TREATING DOCTOR		<input checked="" type="checkbox"/>		

OVER ALL SATISFACTION: ☒ VERY SATISFACTORY / ☒ SATISFIED / ☐ UN SATISFIED

*[Signature]*  
SIGNATURE OF PATIENT

**DEPARTMENT OF PEDIATRIC AND PREVENTIVE DENTISTRY**  
**OUT PATIENT FEEDBACK FROM**

NAME: 1012120006 DATE: 11/12/23  
AGE/SEX: 8/F OP REGIST NO: 72341  
CONTACT NO: 9291300858

RATE YOUR EXPERIENCE WITH THE FOLLOWING ASPECTS OF YOUR VISIT

TITLE	VERY GOOD	GOOD	FAIR	POOR
RECEPTIONIST DESK	<input checked="" type="checkbox"/>			
EASE OF APPOINTMENT	<input checked="" type="checkbox"/>			
TREATMENT DONE	<input checked="" type="checkbox"/>			
TREATING DOCTOR	<input checked="" type="checkbox"/>			

OVER ALL SATISFACTION: ☒ VERY SATISFACTORY / ☒ SATISFIED / ☐ UN SATISFIED

*[Signature]*  
SIGNATURE OF PATIENT

**DEPARTMENT OF PEDIATRIC AND PREVENTIVE DENTISTRY**  
**OUT PATIENT FEEDBACK FROM**

NAME: NIVAN DATE: 2/11/23  
AGE/SEX: 8/M OP REGIST NO: 7200  
CONTACT NO: 9980812798

RATE YOUR EXPERIENCE WITH THE FOLLOWING ASPECTS OF YOUR VISIT

TITLE	VERY GOOD	GOOD	FAIR	POOR
RECEPTIONIST DESK	<input checked="" type="checkbox"/>			
EASE OF APPOINTMENT	<input checked="" type="checkbox"/>			
TREATMENT DONE	<input checked="" type="checkbox"/>			
TREATING DOCTOR	<input checked="" type="checkbox"/>			

OVER ALL SATISFACTION: ☒ VERY SATISFACTORY / ☒ SATISFIED / ☐ UN SATISFIED

*[Signature]*  
SIGNATURE OF PATIENT

**DEPARTMENT OF PEDIATRIC AND PREVENTIVE DENTISTRY**  
**OUT PATIENT FEEDBACK FROM**

NAME: NIVAN DATE: 1/12/23  
AGE/SEX: 10/F OP REGIST NO: 2312010071  
CONTACT NO: 8152073714

RATE YOUR EXPERIENCE WITH THE FOLLOWING ASPECTS OF YOUR VISIT

TITLE	VERY GOOD	GOOD	FAIR	POOR
RECEPTIONIST DESK	<input checked="" type="checkbox"/>			
EASE OF APPOINTMENT	<input checked="" type="checkbox"/>			
TREATMENT DONE	<input checked="" type="checkbox"/>			
TREATING DOCTOR	<input checked="" type="checkbox"/>			

OVER ALL SATISFACTION: ☒ VERY SATISFACTORY / ☒ SATISFIED / ☐ UN SATISFIED

*[Signature]*  
SIGNATURE OF PATIENT

## DEPARTMENT OF CONSERVATIVE DENTISTRY AND ENDODONTICS


DEPARTMENT OF CONSERVATIVE DENTISTRY AND  
ENDODONTICS

## PATIENT FEEDBACK

To provide patient friendly facilities in the hospital, we need your valuable feedback & suggestions.

Name of Patient : Buribye  
Age/Gender : 34/ Female  
Address : Nagadevara Halli,  
Phone No : 07 2284 2531  
OP No : 2305090488  
Email ID :

How do you rate the information given at the Reception Counter?  
☐ Excellent ☐ Good ☒ Average ☐ Poor

How do you rate your reception by oral health care providers during your first visit as a patient?  
☐ Excellent ☒ Good ☐ Average ☐ Poor

How do you rate the overall cleanliness of the department and the facilities provided?  
☐ Excellent ☒ Good ☐ Average ☐ Poor

How do you rate your experience during a subsequent visit to the department?  
☐ Excellent ☒ Good ☐ Average ☐ Poor

How do you rate the treatment services provided at the department?  
☐ Excellent ☒ Good ☐ Average ☐ Poor

How do you rate the emergency treatment services at the hospital?  
☐ Excellent ☒ Good ☐ Average ☐ Poor ☐ Not availed

How do you rate the treatment charges at this hospital?  
☐ Excellent ☐ Good ☒ Average ☐ Poor

What is your overall opinion about the hospital?  
☐ Excellent ☒ Good ☐ Average ☐ Poor

Suggestions (if any)

Signature of Patient

Date: 02-12-2023


DEPARTMENT OF CONSERVATIVE DENTISTRY AND  
ENDODONTICS

## PATIENT FEEDBACK

To provide patient friendly facilities in the hospital, we need your valuable feedback & suggestions.

Name of Patient : Tsering Dekyi  
Age/Gender : 22/ female  
Address : Sheshnigvi Halli, Yama Raja,  
Phone No : 9596447928  
OP No : 2312050311  
Email ID :

How do you rate the information given at the Reception Counter?  
☐ Excellent ☒ Good ☐ Average ☐ Poor

How do you rate your reception by oral health care providers during your first visit as a patient?  
☒ Excellent ☐ Good ☐ Average ☐ Poor

How do you rate the overall cleanliness of the department and the facilities provided?  
☐ Excellent ☐ Good ☒ Average ☐ Poor

How do you rate your experience during a subsequent visit to the department?  
☒ Excellent ☐ Good ☐ Average ☐ Poor

How do you rate the treatment services provided at the department?  
☒ Excellent ☐ Good ☐ Average ☐ Poor

How do you rate the emergency treatment services at the hospital?  
☒ Excellent ☐ Good ☐ Average ☐ Poor ☐ Not availed

How do you rate the treatment charges at this hospital?  
☐ Excellent ☒ Good ☐ Average ☐ Poor

What is your overall opinion about the hospital?  
☒ Excellent ☐ Good ☐ Average ☐ Poor

Suggestions (if any)

Signature of Patient

Date: 02-12-2023


DEPARTMENT OF CONSERVATIVE DENTISTRY AND  
ENDODONTICS

## PATIENT FEEDBACK

To provide patient friendly facilities in the hospital, we need your valuable feedback & suggestions.

Name of Patient : Vadina  
Age/Gender : 41/ male  
Address : Kengeri upa nagar  
Phone No : 9901478829  
OP No : 2312010306  
Email ID :

How do you rate the information given at the Reception Counter?  
☒ Excellent ☐ Good ☐ Average ☐ Poor

How do you rate your reception by oral health care providers during your first visit as a patient?  
☒ Excellent ☐ Good ☐ Average ☐ Poor

How do you rate the overall cleanliness of the department and the facilities provided?  
☒ Excellent ☐ Good ☐ Average ☐ Poor

How do you rate your experience during a subsequent visit to the department?  
☒ Excellent ☐ Good ☐ Average ☐ Poor

How do you rate the treatment services provided at the department?  
☐ Excellent ☒ Good ☐ Average ☐ Poor

How do you rate the emergency treatment services at the hospital?  
☐ Excellent ☐ Good ☒ Average ☐ Poor ☐ Not availed

How do you rate the treatment charges at this hospital?  
☐ Excellent ☐ Good ☒ Average ☐ Poor

What is your overall opinion about the hospital?  
☐ Excellent ☒ Good ☐ Average ☐ Poor

Suggestions (if any)

Signature of Patient

Date: 18-12-2023


DEPARTMENT OF CONSERVATIVE DENTISTRY AND  
ENDODONTICS

## PATIENT FEEDBACK

To provide patient friendly facilities in the hospital, we need your valuable feedback & suggestions.

Name of Patient : Kamalanma  
Age/Gender : 53/ Female  
Address : Bangalore University  
Phone No : 7760278445  
OP No : 2311150260  
Email ID :

How do you rate the information given at the Reception Counter?  
☒ Excellent ☐ Good ☐ Average ☐ Poor

How do you rate your reception by oral health care providers during your first visit as a patient?  
☐ Excellent ☒ Good ☐ Average ☐ Poor

How do you rate the overall cleanliness of the department and the facilities provided?  
☐ Excellent ☐ Good ☒ Average ☐ Poor

How do you rate your experience during a subsequent visit to the department?  
☒ Excellent ☐ Good ☐ Average ☐ Poor

How do you rate the treatment services provided at the department?  
☒ Excellent ☐ Good ☐ Average ☐ Poor

How do you rate the emergency treatment services at the hospital?  
☐ Excellent ☒ Good ☐ Average ☐ Poor ☐ Not availed

How do you rate the treatment charges at this hospital?  
☐ Excellent ☒ Good ☐ Average ☐ Poor

What is your overall opinion about the hospital?  
☐ Excellent ☒ Good ☐ Average ☐ Poor

Suggestions (if any)

Signature of Patient

Date: 11-12-2023



## DEPARTMENT OF CONSERVATIVE DENTISTRY AND ENDODONTICS

**DEPARTMENT OF CONSERVATIVE DENTISTRY AND ENDODONTICS**

**PATIENT FEEDBACK**

To provide patient friendly facilities in the hospital, we need your valuable feedback & suggestions.

Name of Patient : Nagathara V  
 Age/Gender : 30/Female  
 Address : Rama Nagar  
 Phone No : 9731333526  
 OP No : 2310160308  
 Email ID :

How do you rate the information given at the Reception Counter?  
☒ Excellent ☐ Good ☐ Average ☐ Poor

How do you rate your reception by oral health care providers during your first visit as a patient?  
☐ Excellent ☒ Good ☐ Average ☐ Poor

How do you rate the overall cleanliness of the department and the facilities provided?  
☐ Excellent ☒ Good ☐ Average ☐ Poor

How do you rate your experience during a subsequent visit to the department?  
☐ Excellent ☒ Good ☐ Average ☐ Poor

How do you rate the treatment services provided at the department?  
☐ Excellent ☒ Good ☐ Average ☐ Poor

How do you rate the emergency treatment services at the hospital?  
☐ Excellent ☒ Good ☐ Average ☐ Poor ☐ Not availed

How do you rate the treatment charges at this hospital?  
☐ Excellent ☒ Good ☐ Average ☐ Poor

What is your overall opinion about the hospital?  
☐ Excellent ☒ Good ☐ Average ☐ Poor

Suggestions (if any)

Signature of Patient Date: 14-12-2023

## DEPARTMENT OF ORTHODONTICS AND DENTOFACIAL ORTHOPEDICS

**RRDCH/NABH/ORTHO/07**

**Patient Complaints/ Feedback Form**

Date 24/11/23

Name: Suhag. m  
 Age/sex: male - 21  
 Op Registration number: 230306058  
 Contact number: 7996653990  
 Nature of complain:

Nature of feedback:  
I am satisfied with doctor and treatment and college are very cooperative and helped me understand the treatment process. I am happy with my treatment

Signature of patient

**RRDCH/NABH/ORTHO/07**

**Patient Complaints/ Feedback Form**

Date 22/12/23

Name: Bhuvana  
 Age/sex: 13yrs/Female  
 Op Registration number: 2107260030  
 Contact number: 9686196974  
 Nature of complain:

Nature of feedback:  
I am satisfied with the treatment and doctor. Doctors are very cooperative and understanding - I am happy with my clip treatment

Signature of patient

## DEPARTMENT OF IMPLANTOLOGY

### PATIENT COMPLAINTS /FEEDBACK FORM

NAME: [REDACTED] Date: 28/12/23  
 AGE/SEX: 18 y  
 REGISTRATION NUMBER: 2211260026  
 CONTACT NUMBER: [REDACTED]  
 NATURE OF COMPLAINT:  
 pt clo missing teeth in @ lower back both region &  
 wants to get it replaced

NATURE OF FEEDBACK:  
 I have got good response from the doctor. All  
 the procedures went good and got a successful  
 tooth implant. Thank you

SIGNATURE OF PATIENT

### PATIENT COMPLAINTS /FEEDBACK FORM

NAME: [REDACTED] Date: 28/12/2023  
 AGE/SEX: Male  
 OP REGISTRATION NUMBER: 2102130022  
 CONTACT NUMBER: [REDACTED]  
 NATURE OF COMPLAINT:  
 N/A

NATURE OF FEEDBACK:  
 • Had Tooth Implant  
 @ Cost :- Affordable  
 @ Service :- Staff were doing the needful  
 @ Treatment :- It was smooth  
 Overall the process went good did not have  
 any issue

SIGNATURE OF PATIENT

### PATIENT COMPLAINTS /FEEDBACK FORM

NAME: [REDACTED] Date: 27.12.23  
 AGE/SEX: 28  
 REGISTRATION NUMBER: 49565  
 CONTACT NUMBER: [REDACTED]  
 NATURE OF COMPLAINT:

NATURE OF FEEDBACK:  
 Overall I'm happy with the implants and  
 how it looks.  
 I'd like to thank Dr. Deepika for constantly  
 following on my case and making it quicker.

### PATIENT COMPLAINTS /FEEDBACK FORM

NAME: [REDACTED] Date: 15/12/2023  
 AGE/SEX: 23 years  
 REGISTRATION NUMBER:  
 CONTACT NUMBER: [REDACTED]  
 NATURE OF COMPLAINT:

NATURE OF FEEDBACK:  
 Overall I'm happy with the implants and  
 how it looks. I'd like to thank Dr. Deepika for  
 constantly following on my case and making it  
 quicker.

SIGNATURE OF PATIENT



RajaRajeswari Dental College and Hospital, Bengaluru

# 14, Ramohalli Cross, Mysore Road, Bengaluru-560074. KARNATAKA. Phone: 080 28437150, Fax: 080 28437468.

E-mail: principalrrdch@gmail.com www.rrdch.org www.rrdch.edu.in